Dermatopathology Slide Review Part 111

Paul K. Shitabata, M.D.
Dermatopathology Institute
Torrance, CA

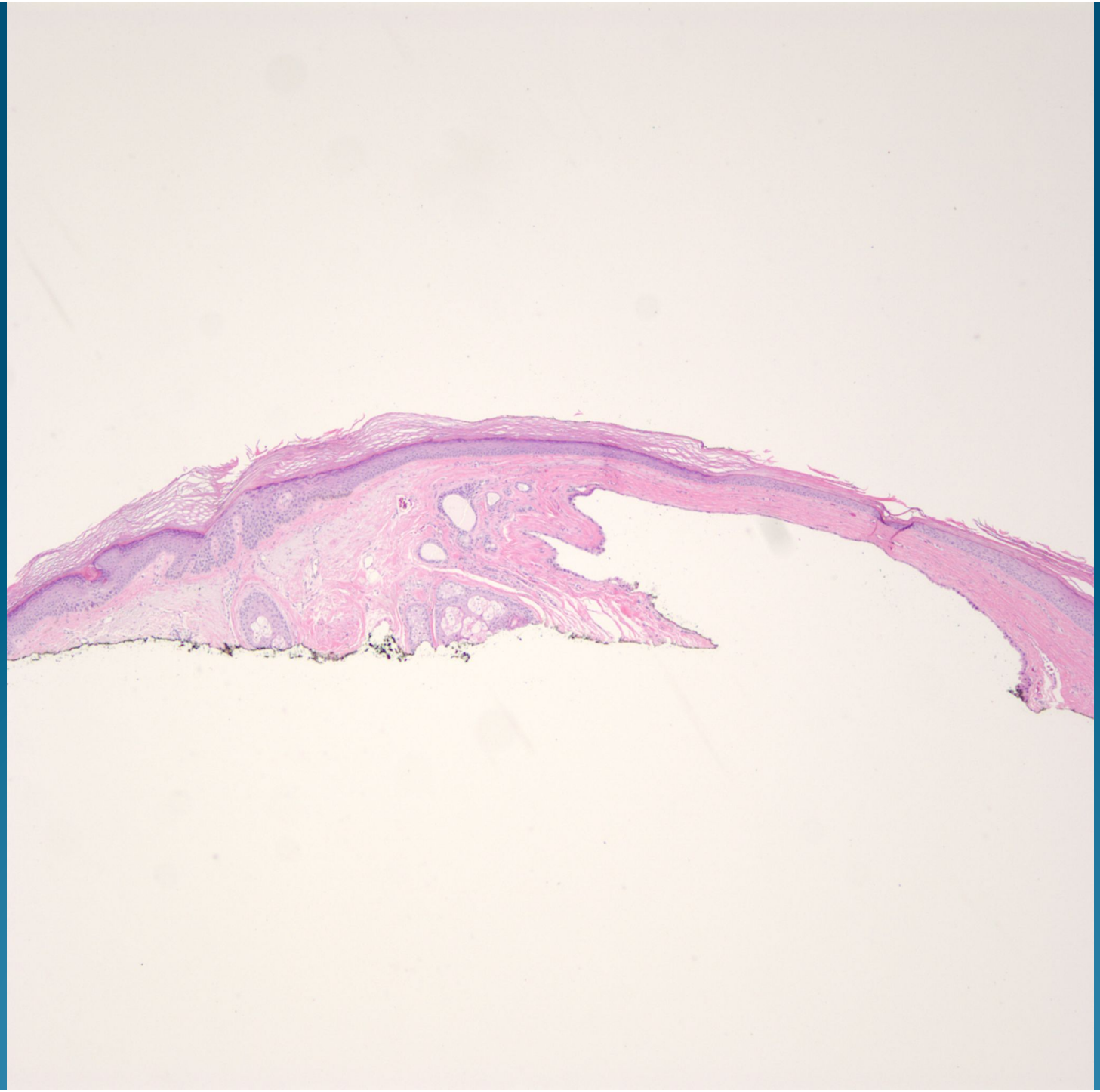

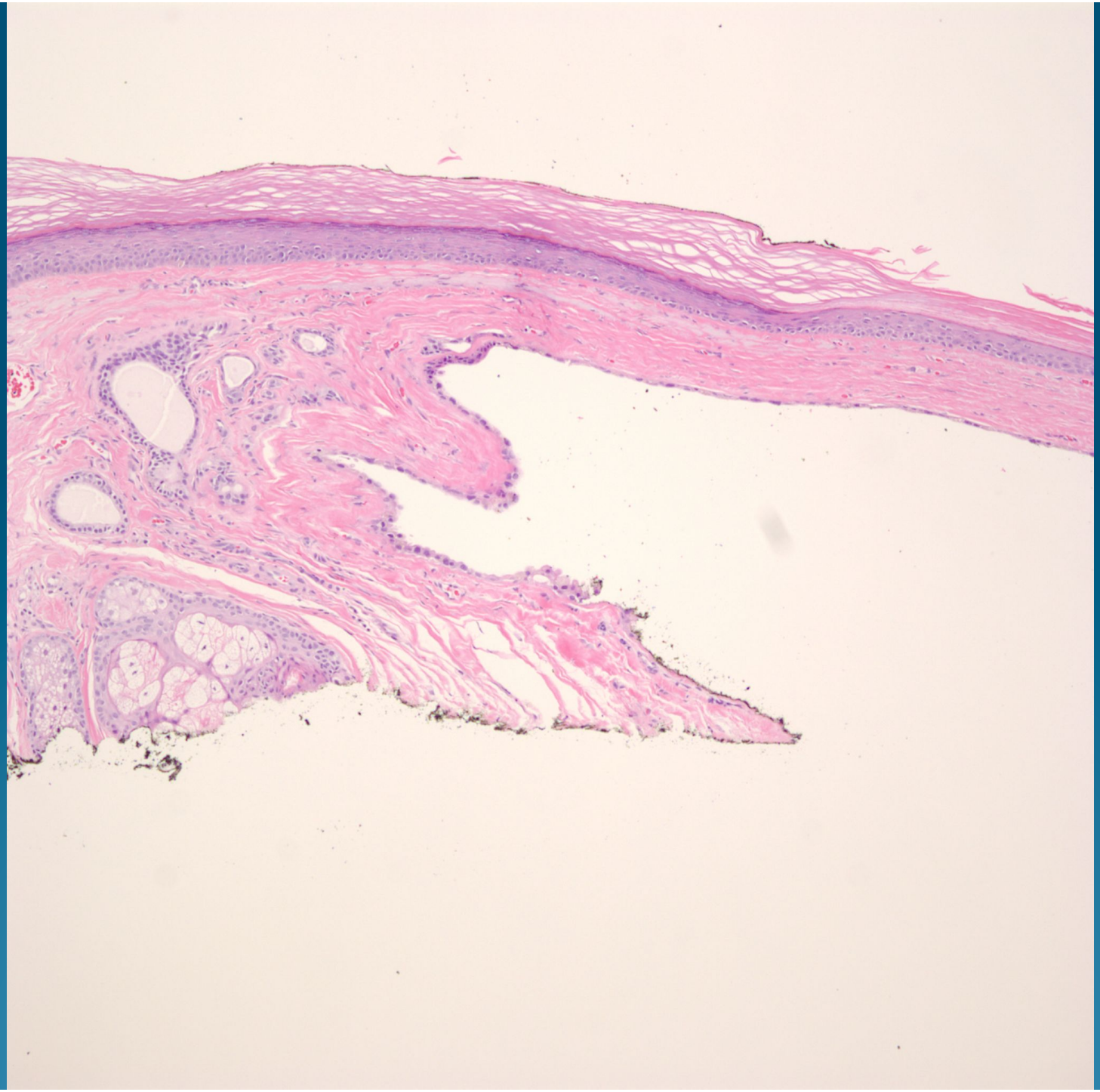

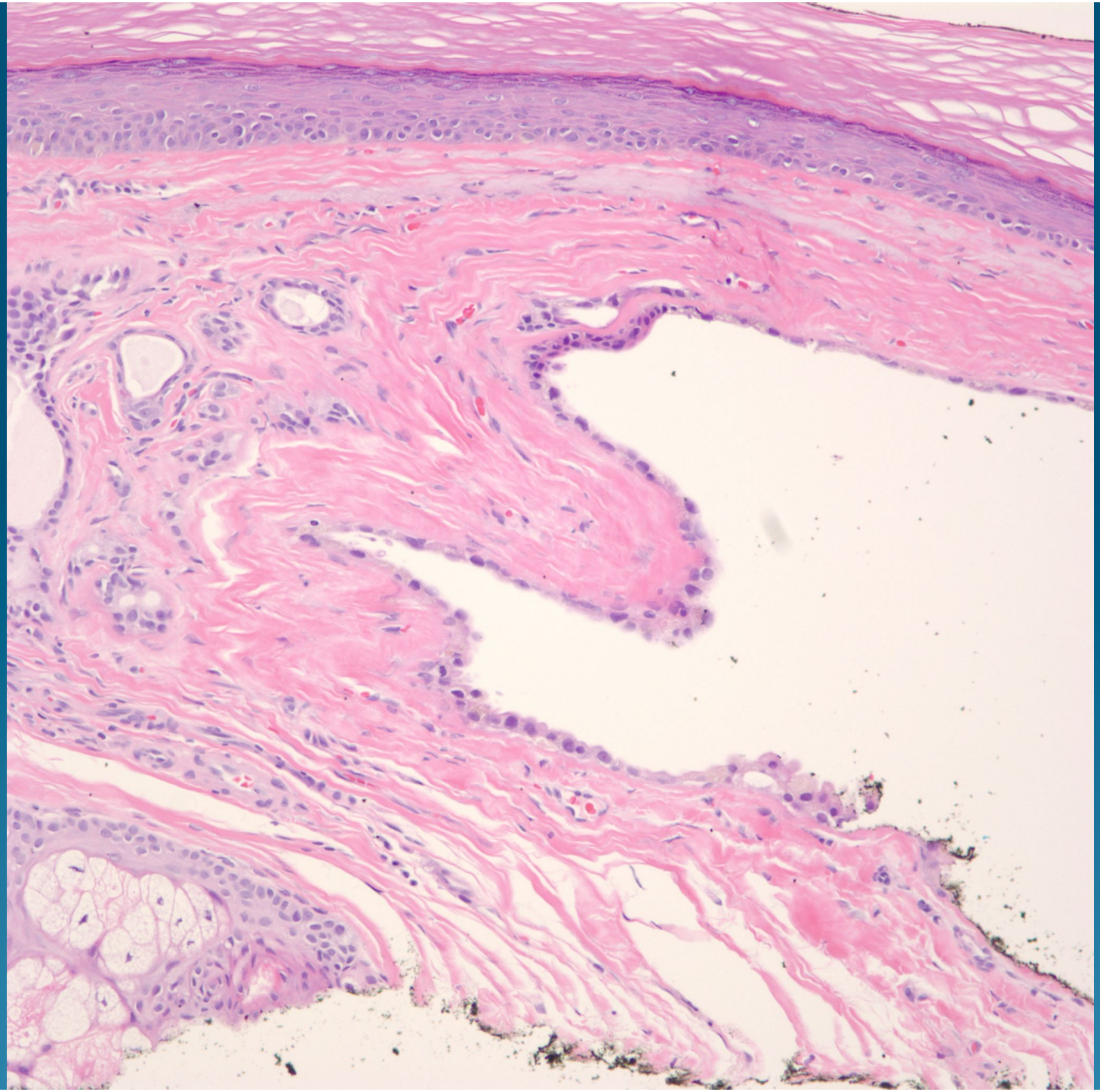

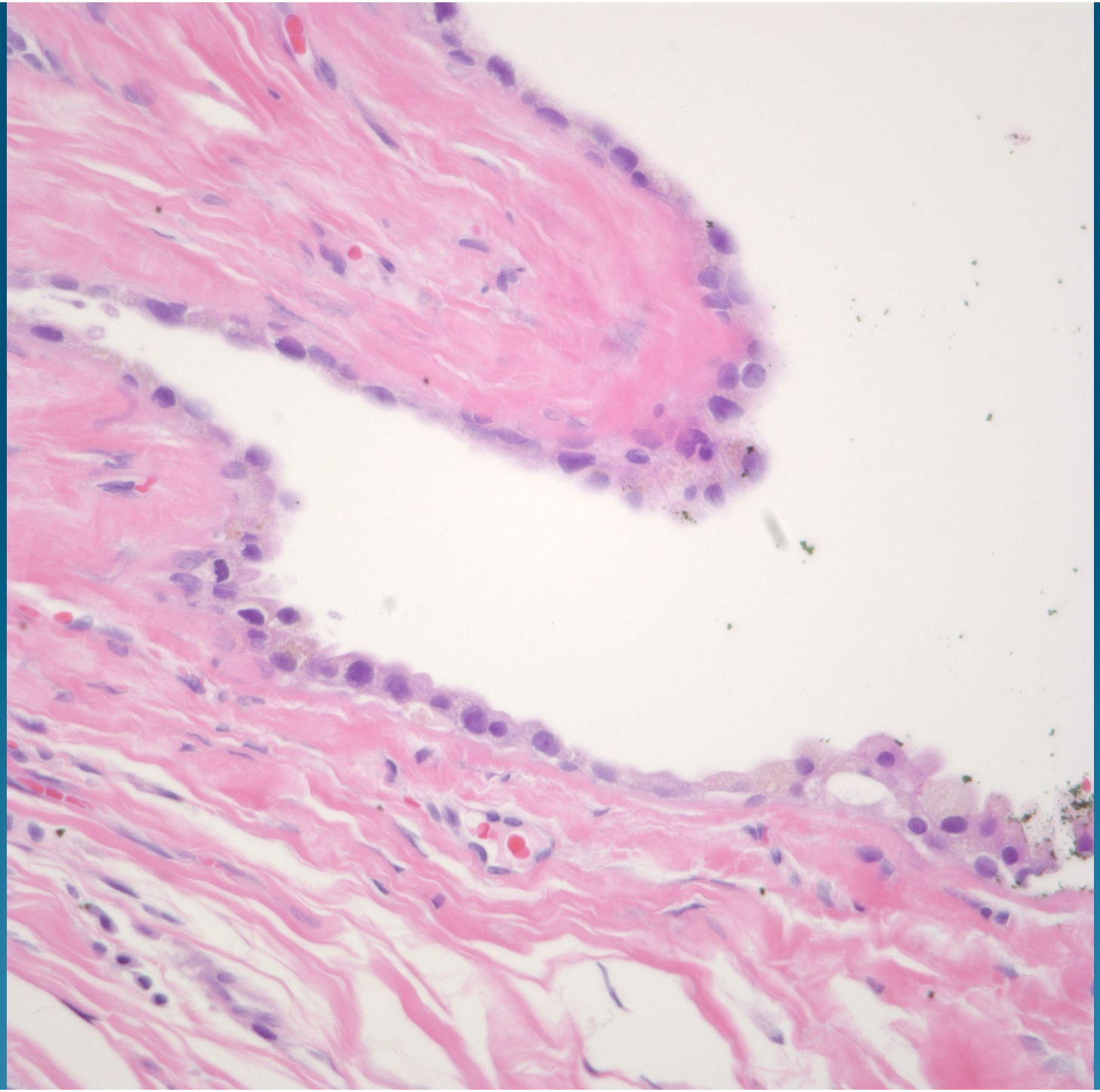

What is the best diagnosis?

A. Hidrocystoma
B. Pilar cyst
C. Cystic basal cell carcinoma
D. Cystic hidradenoma
E. Syringocystadenoma papilliferum

Apocrine hidrocystoma

Cyst lined by apocrine epithelium

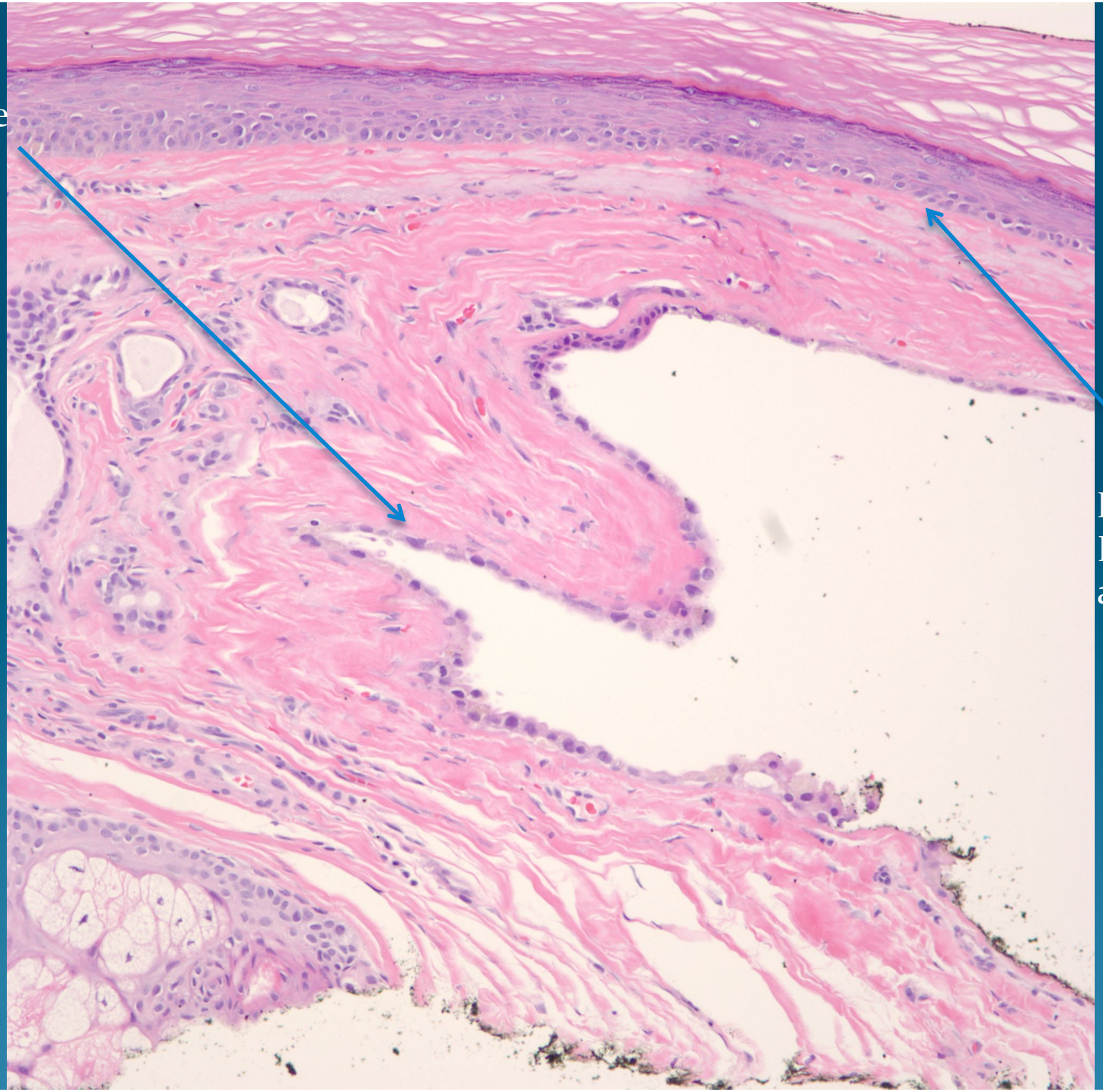

No Epidermal attachment

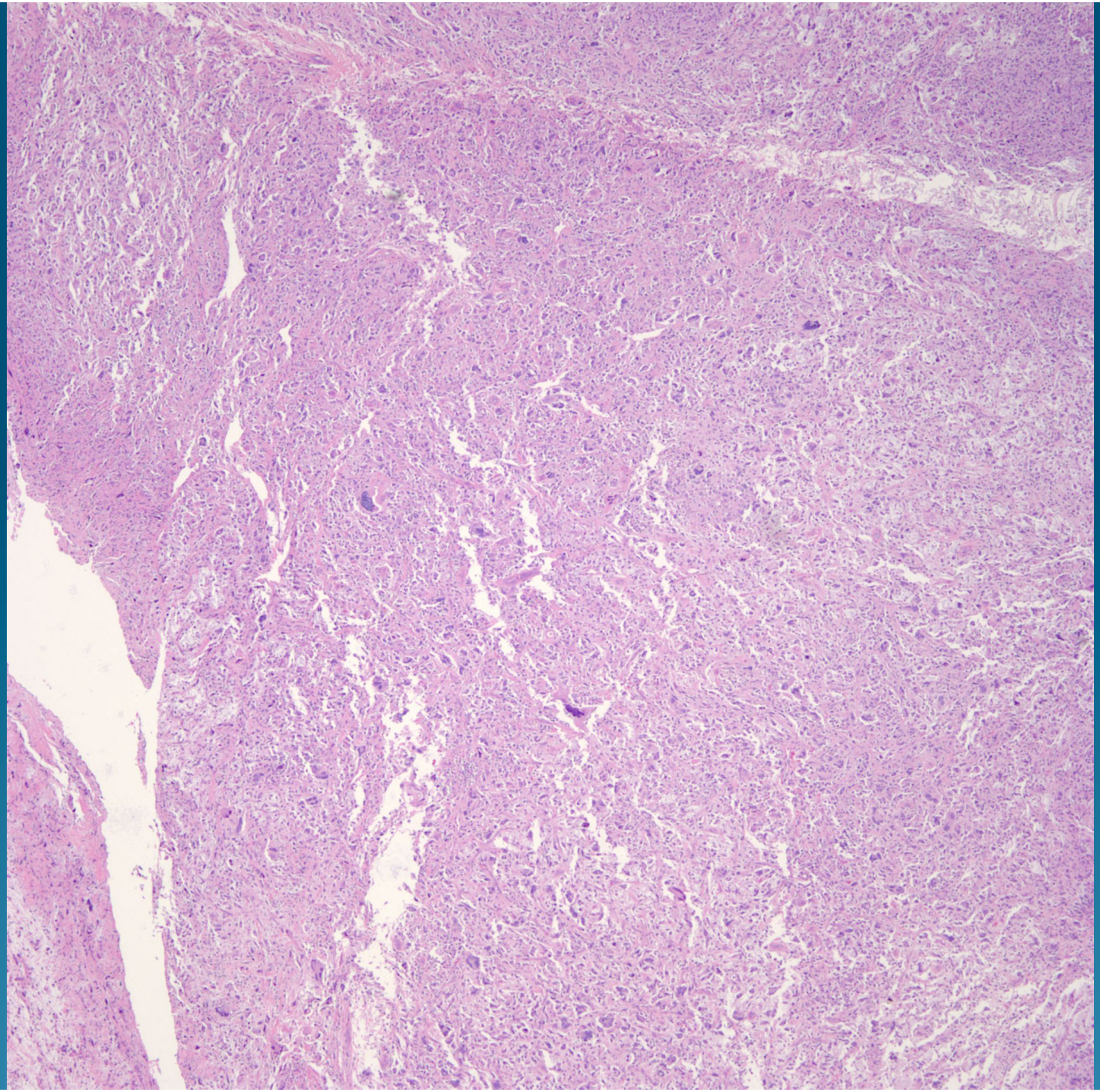

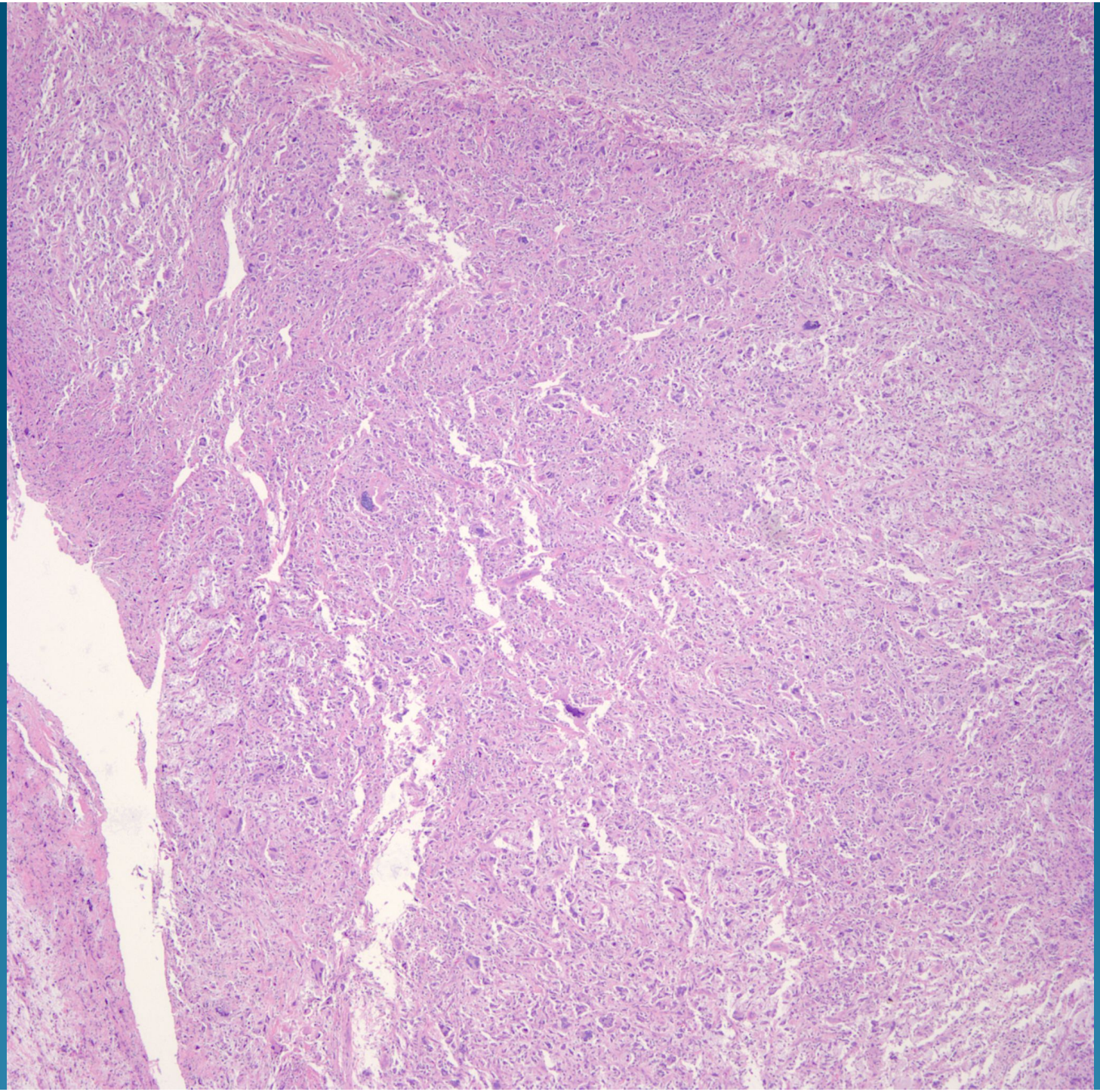

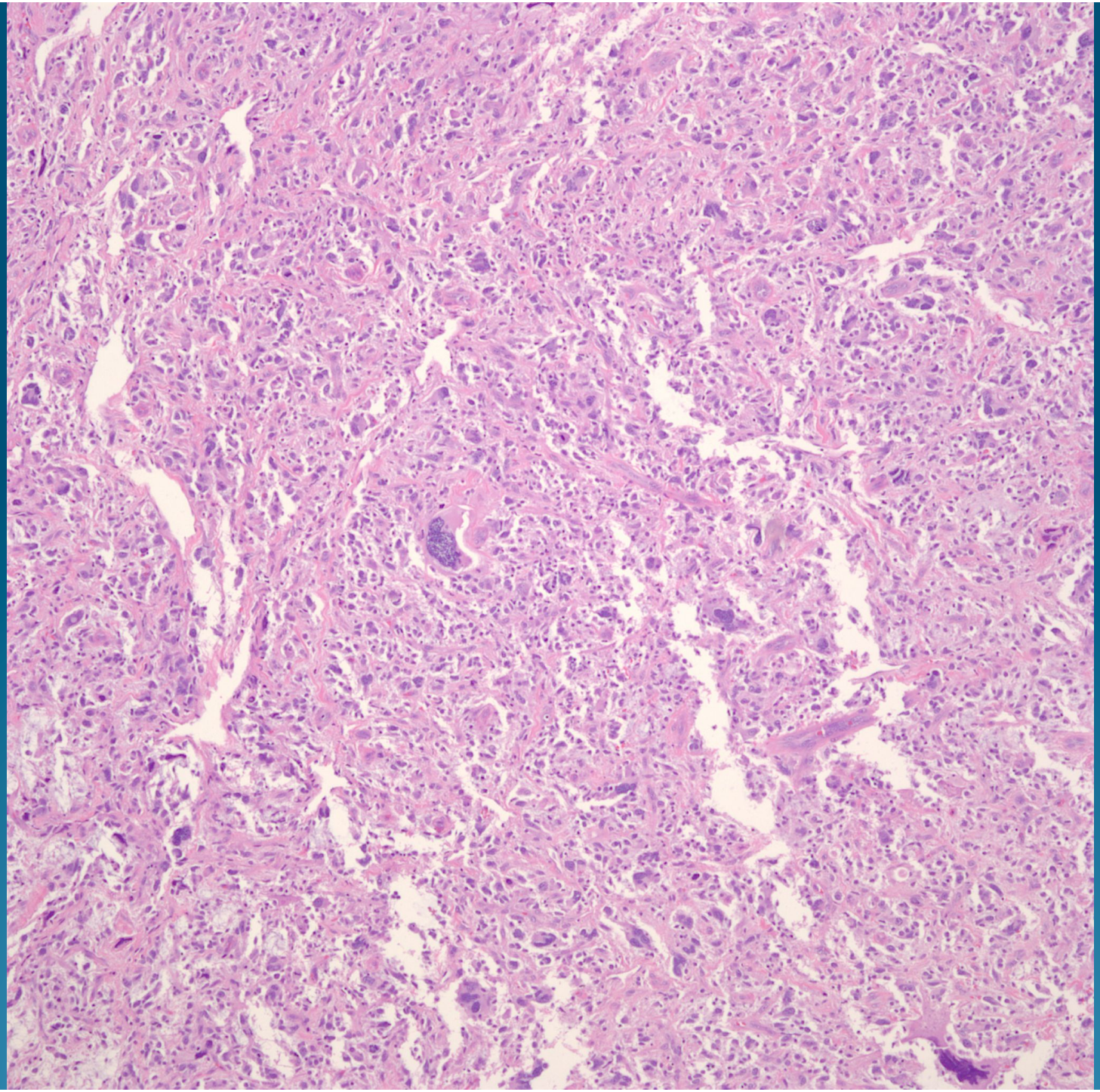

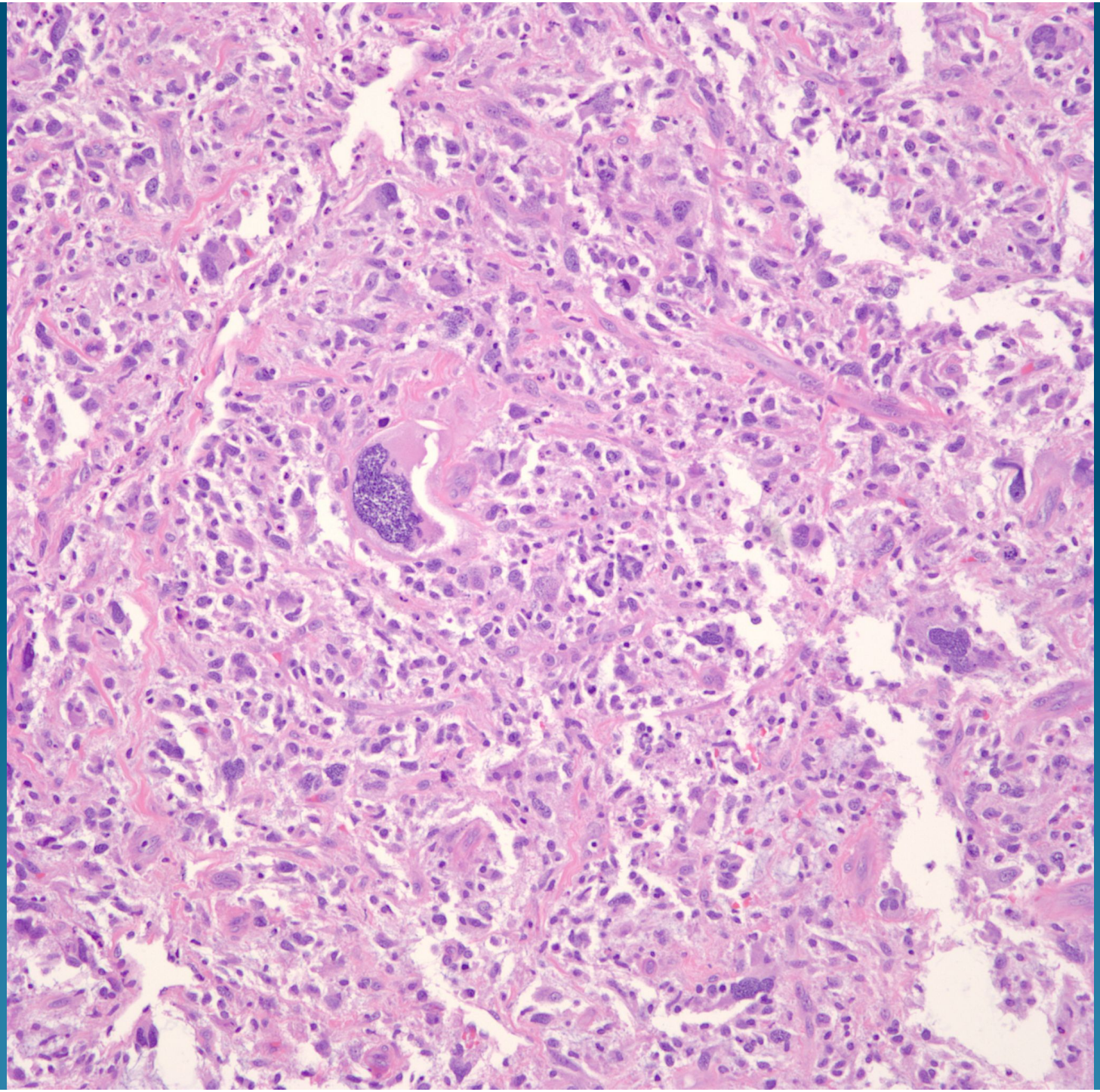

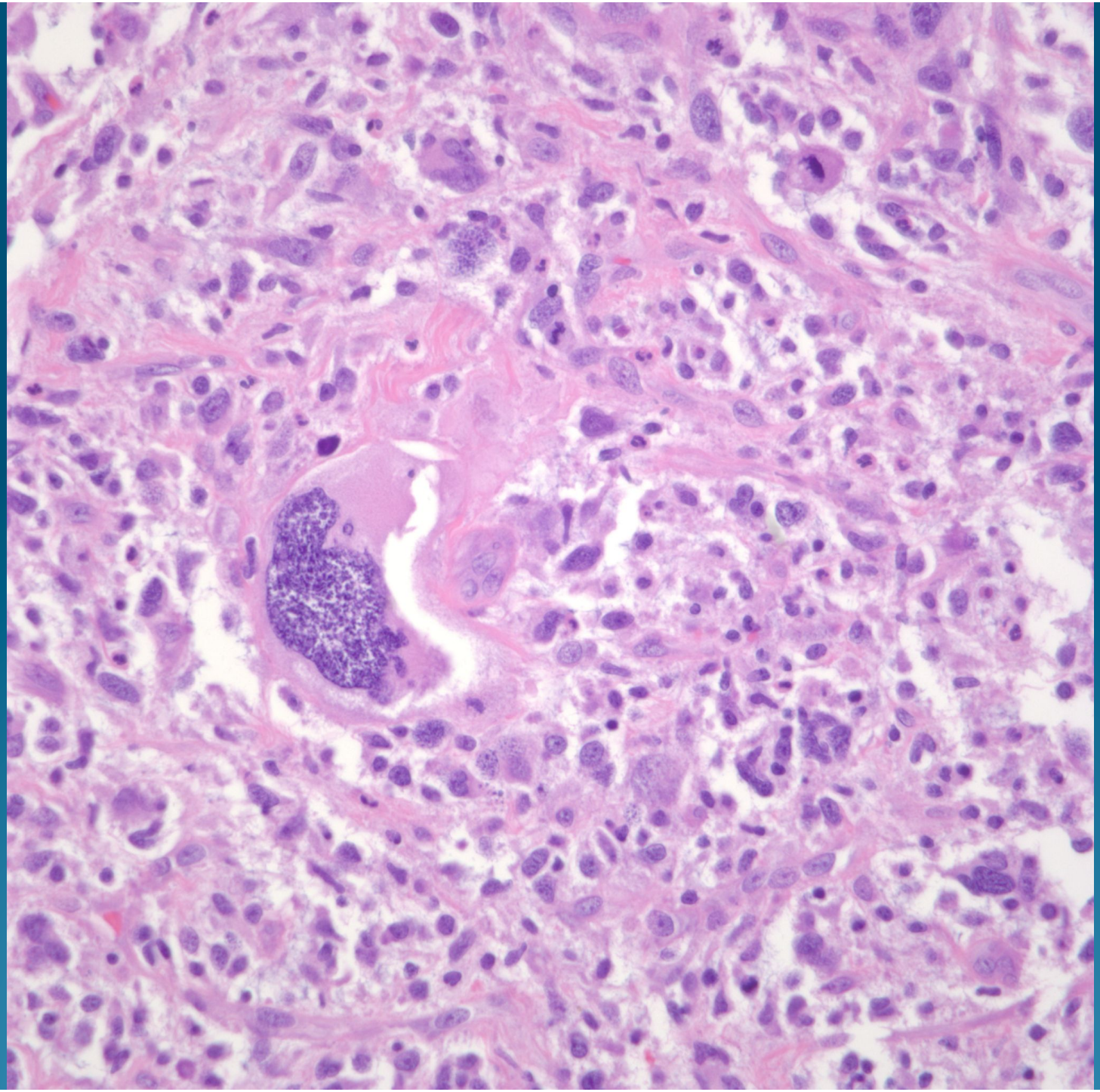

Malignant Fibrous Histiocytoma, arising within chest wall

Usually deep soft tissue location

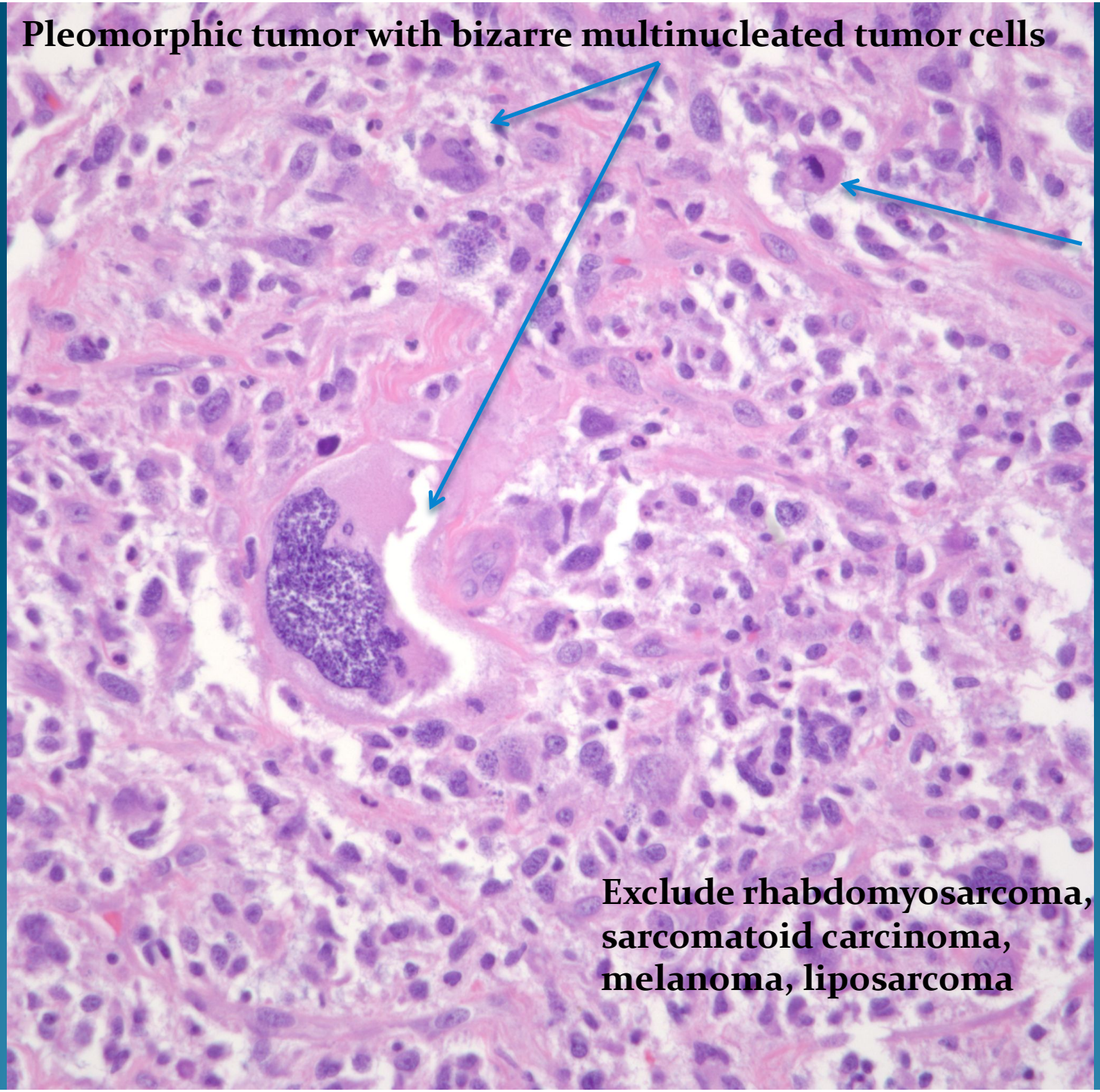

Atypical mitotic figures

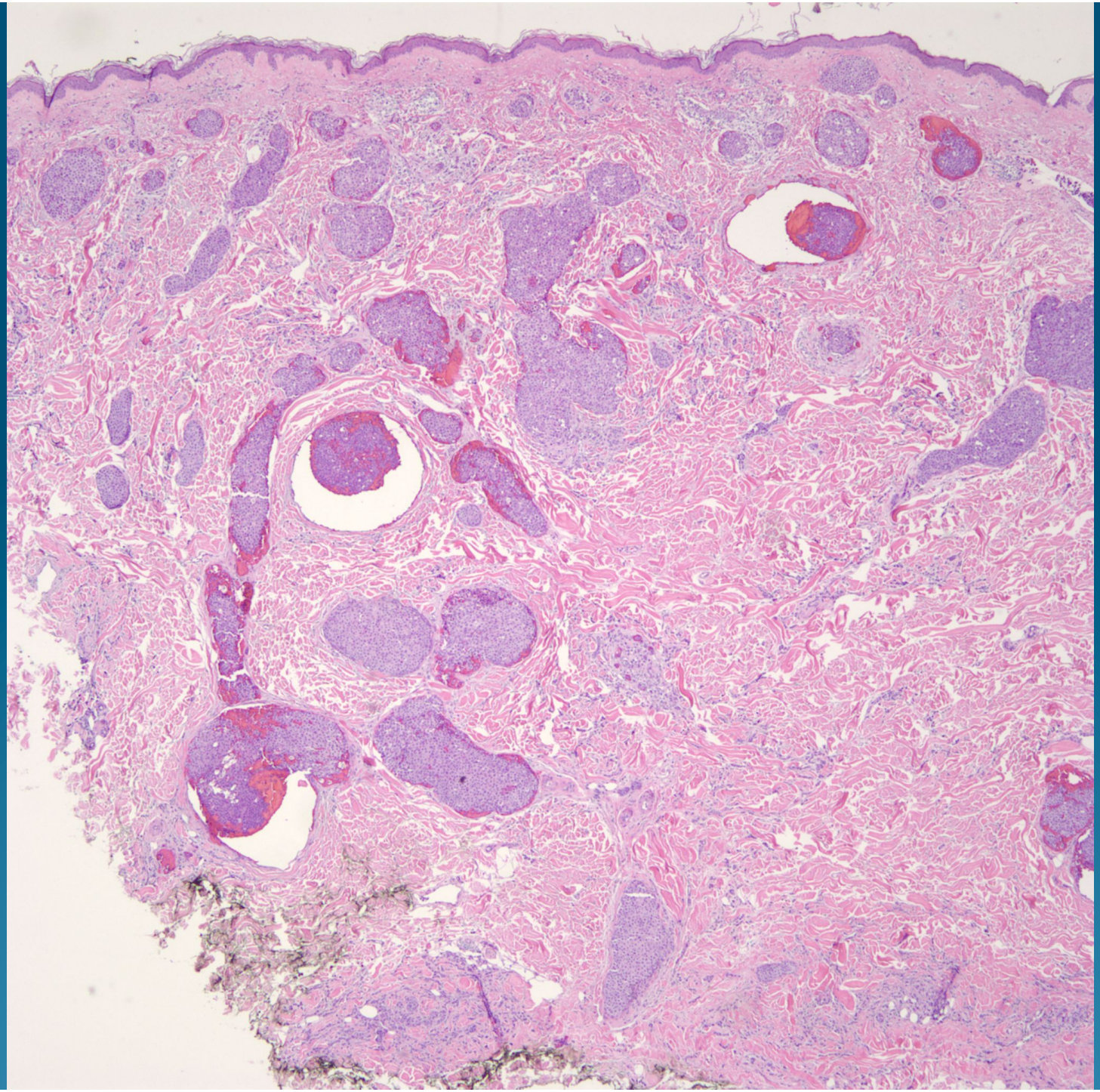

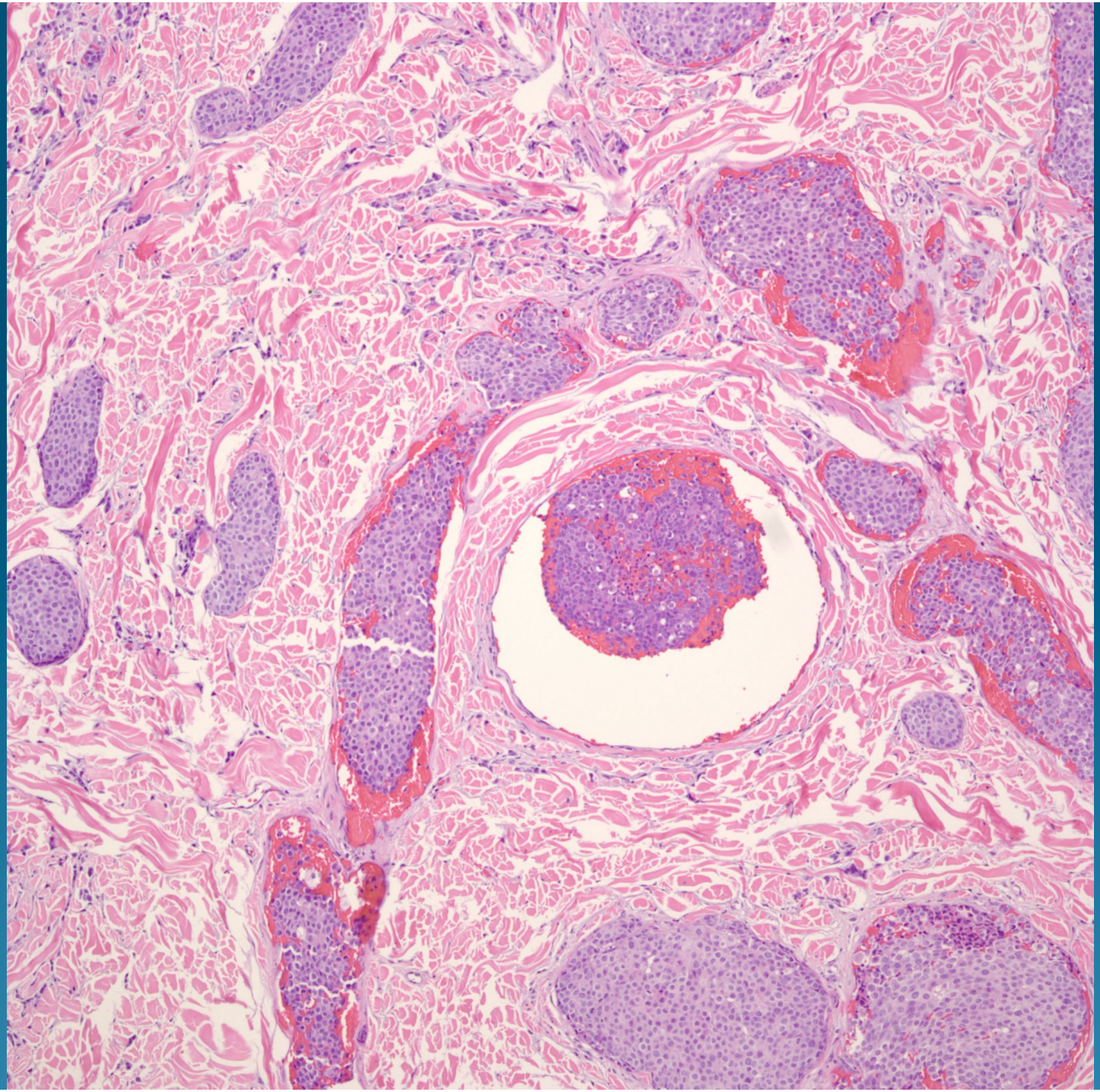

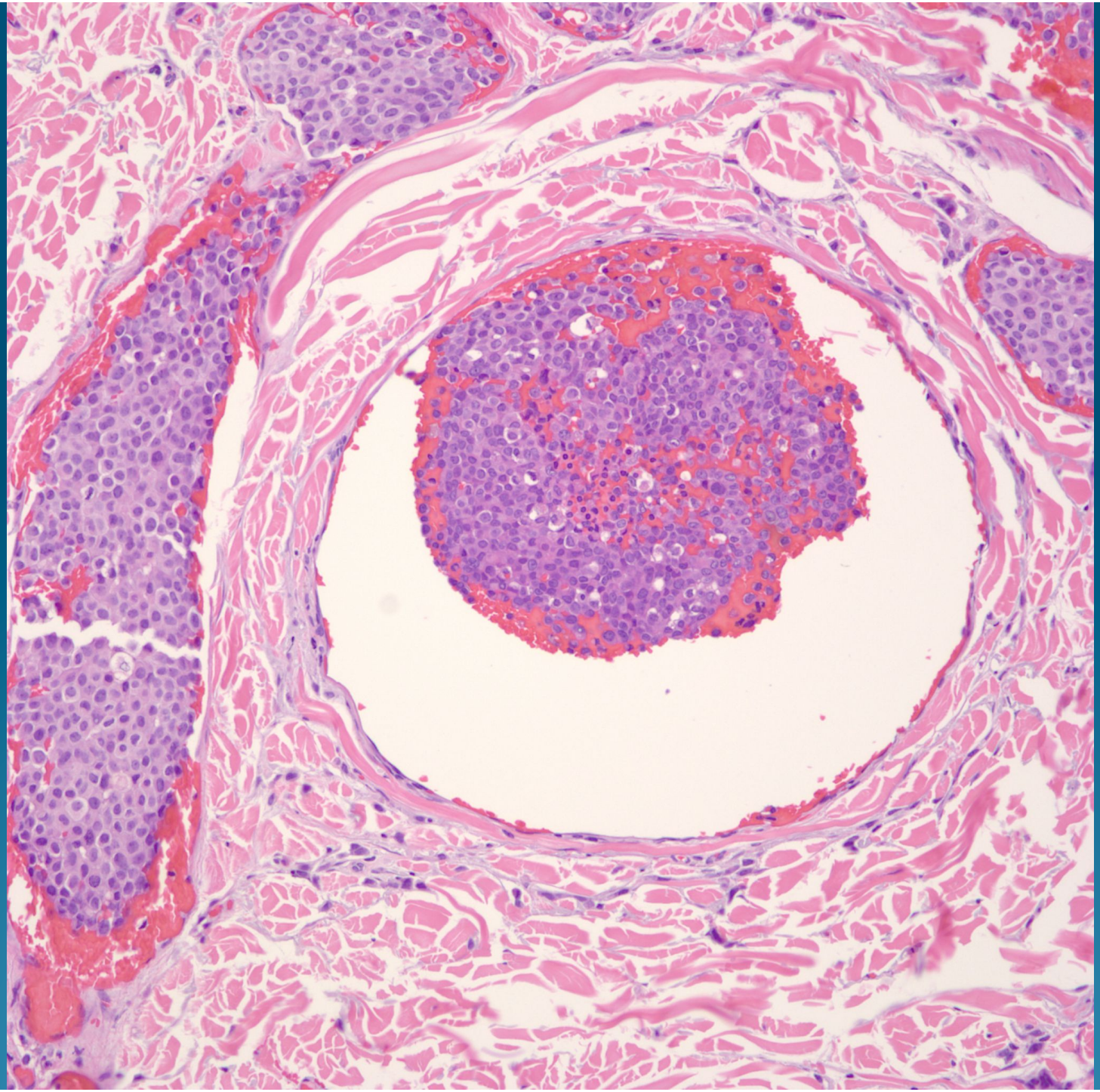

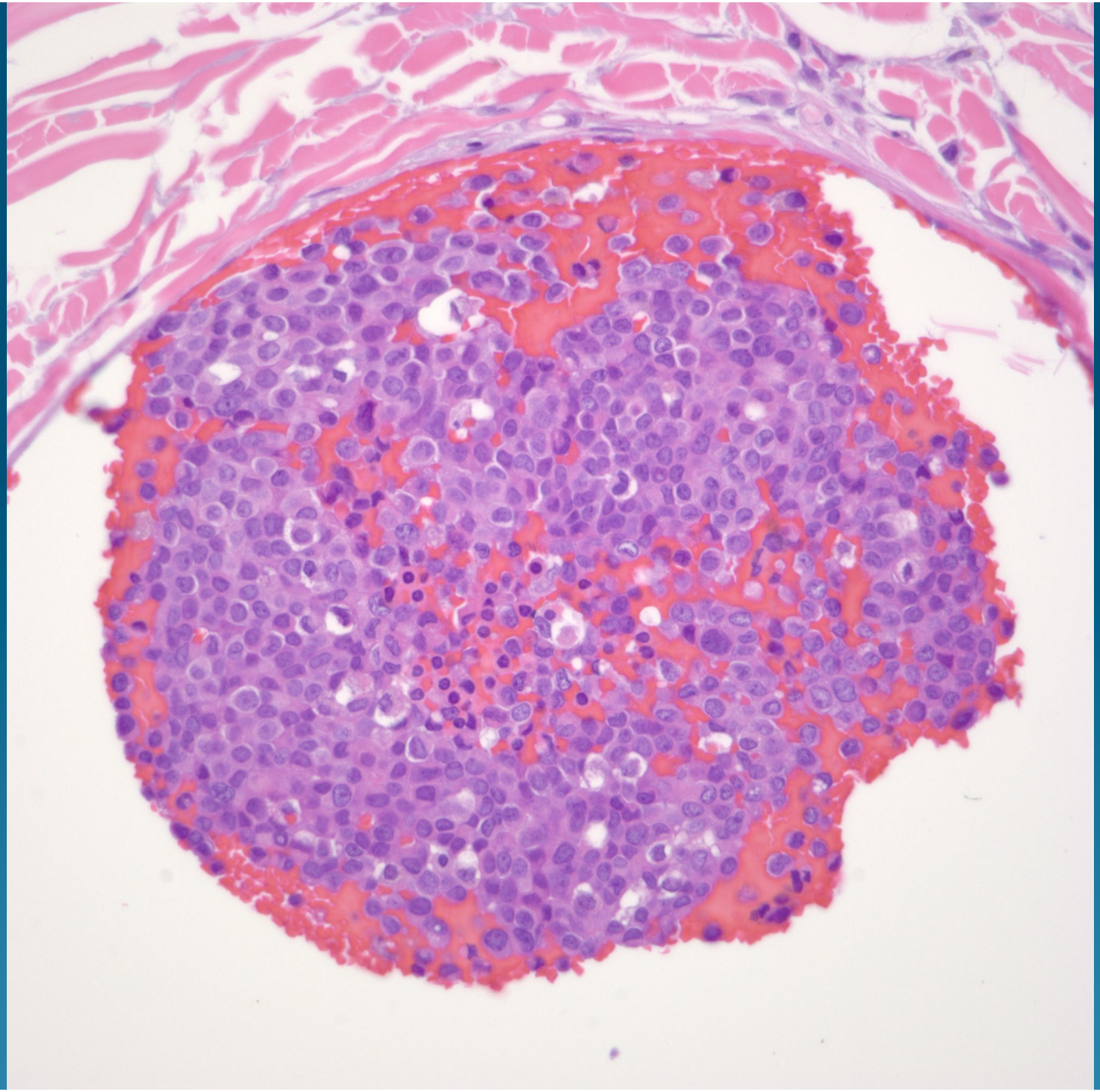

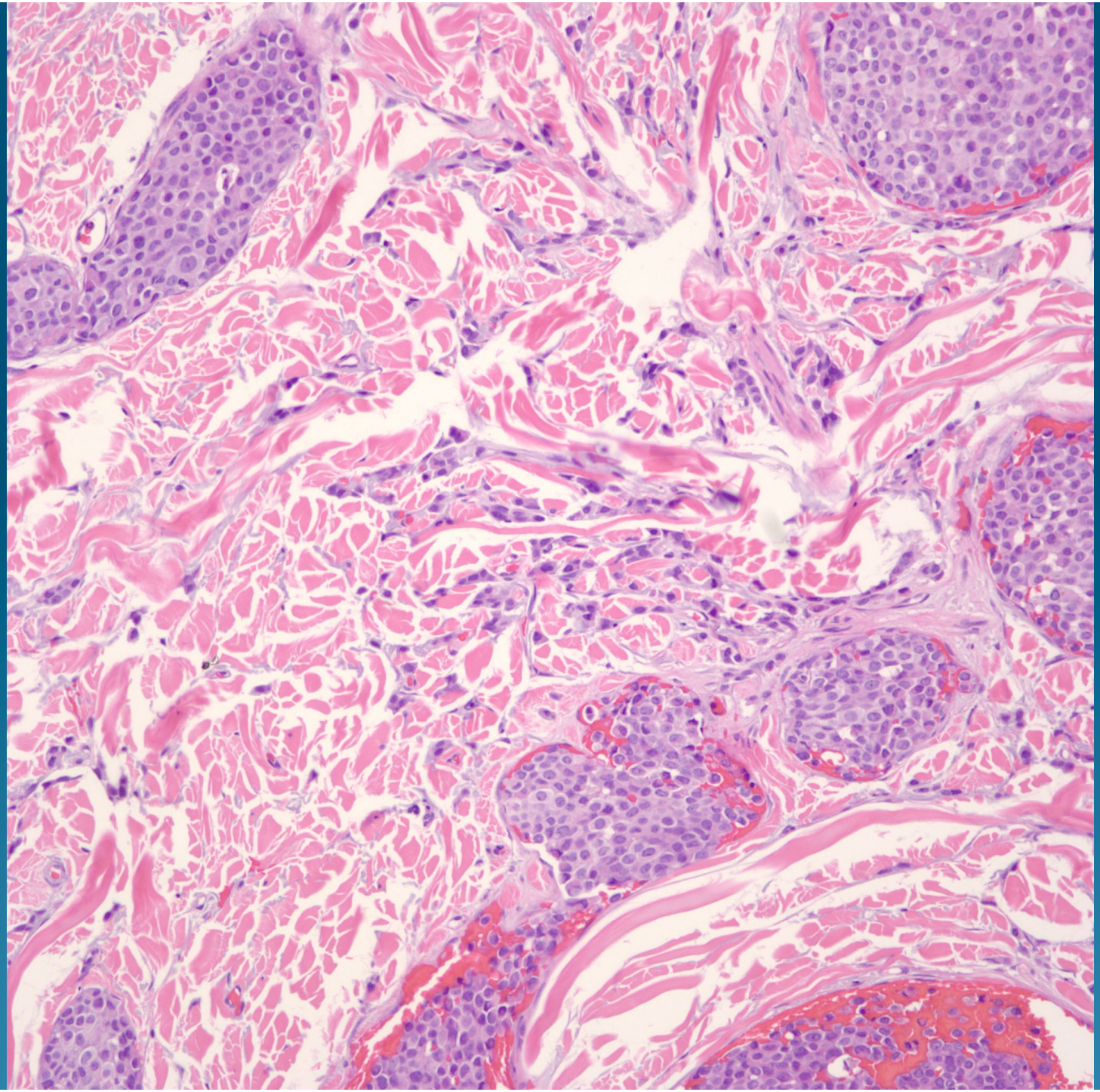

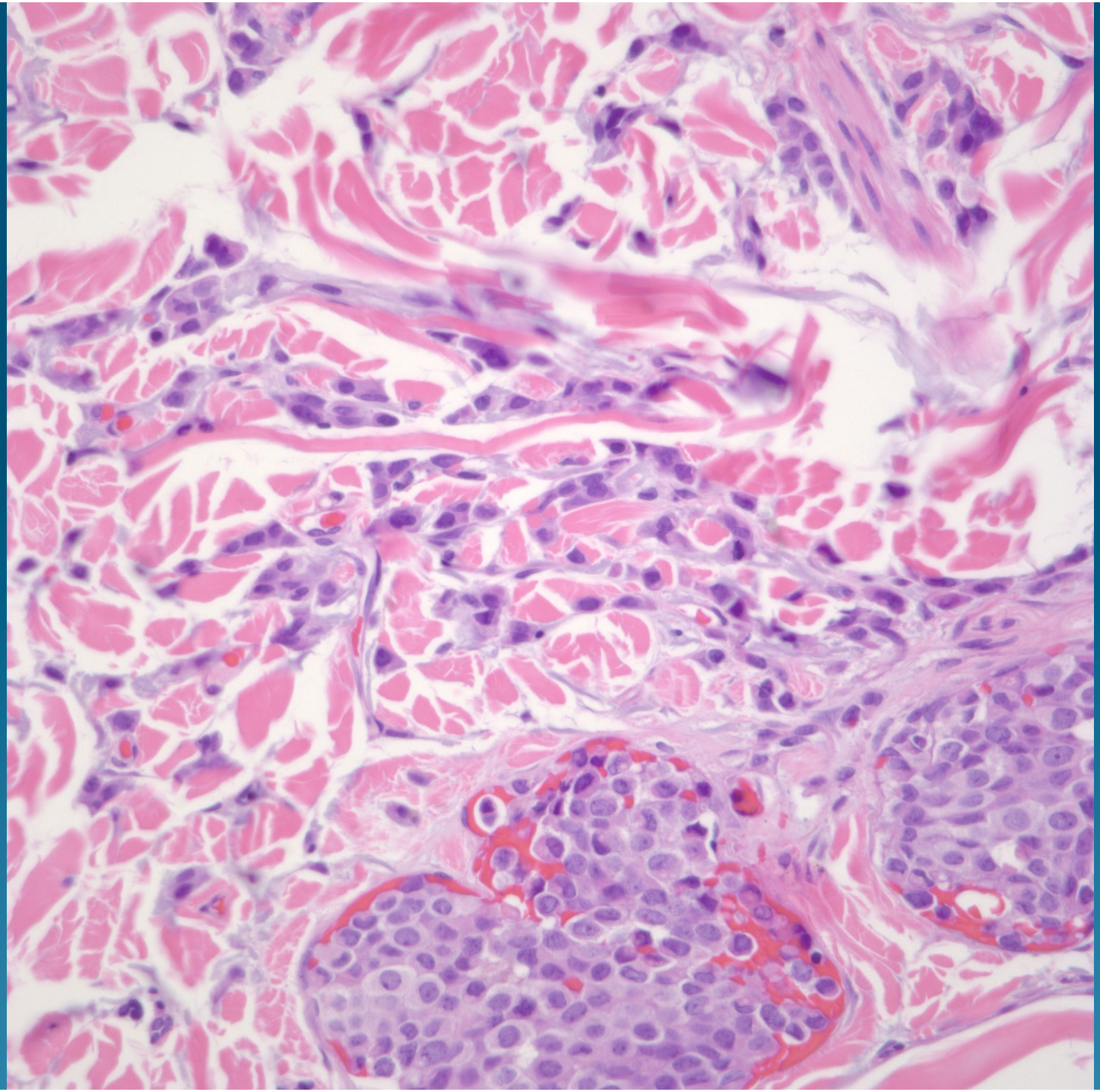

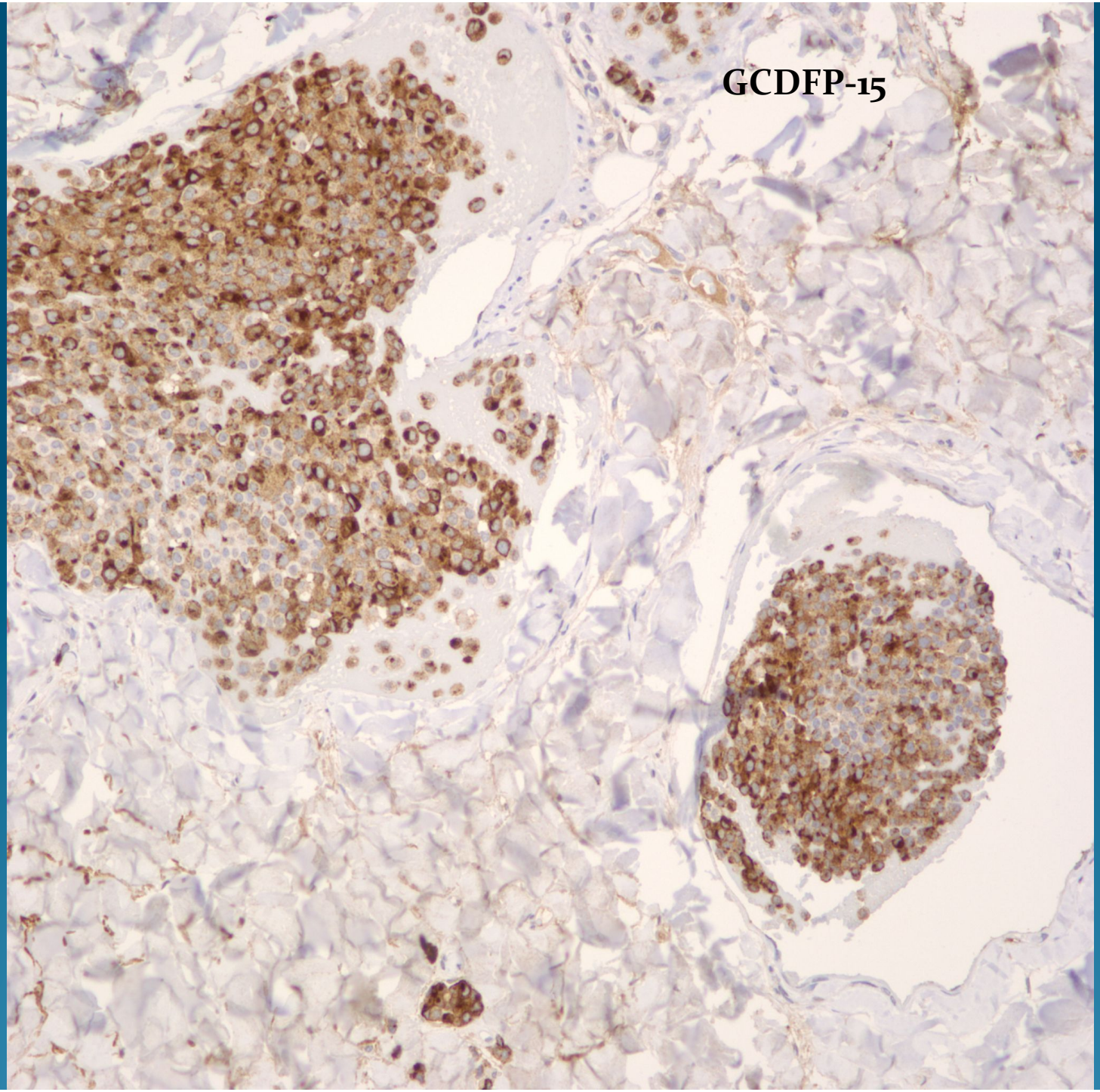
GCDFP-15

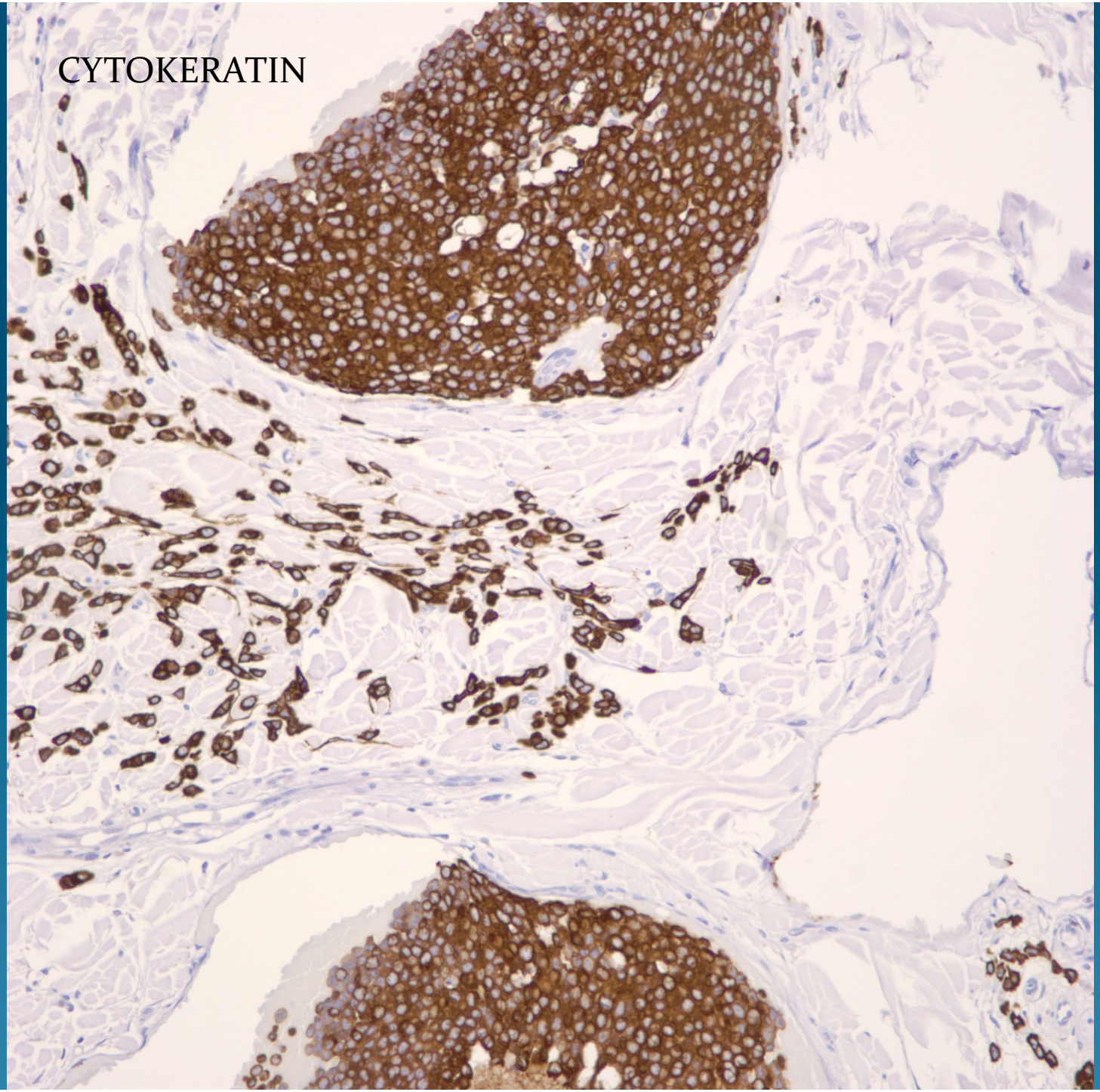
CYTOKERATIN

What is the best diagnosis?

A. Metastatic melanoma
B. Angiosarcoma
C. Metastatic carcinoma
D. Intravascular lymphoma
E. Nodular hidradenoma

Metastatic Carcinoma,
Consistent with Primary Lobular CA
of the breast

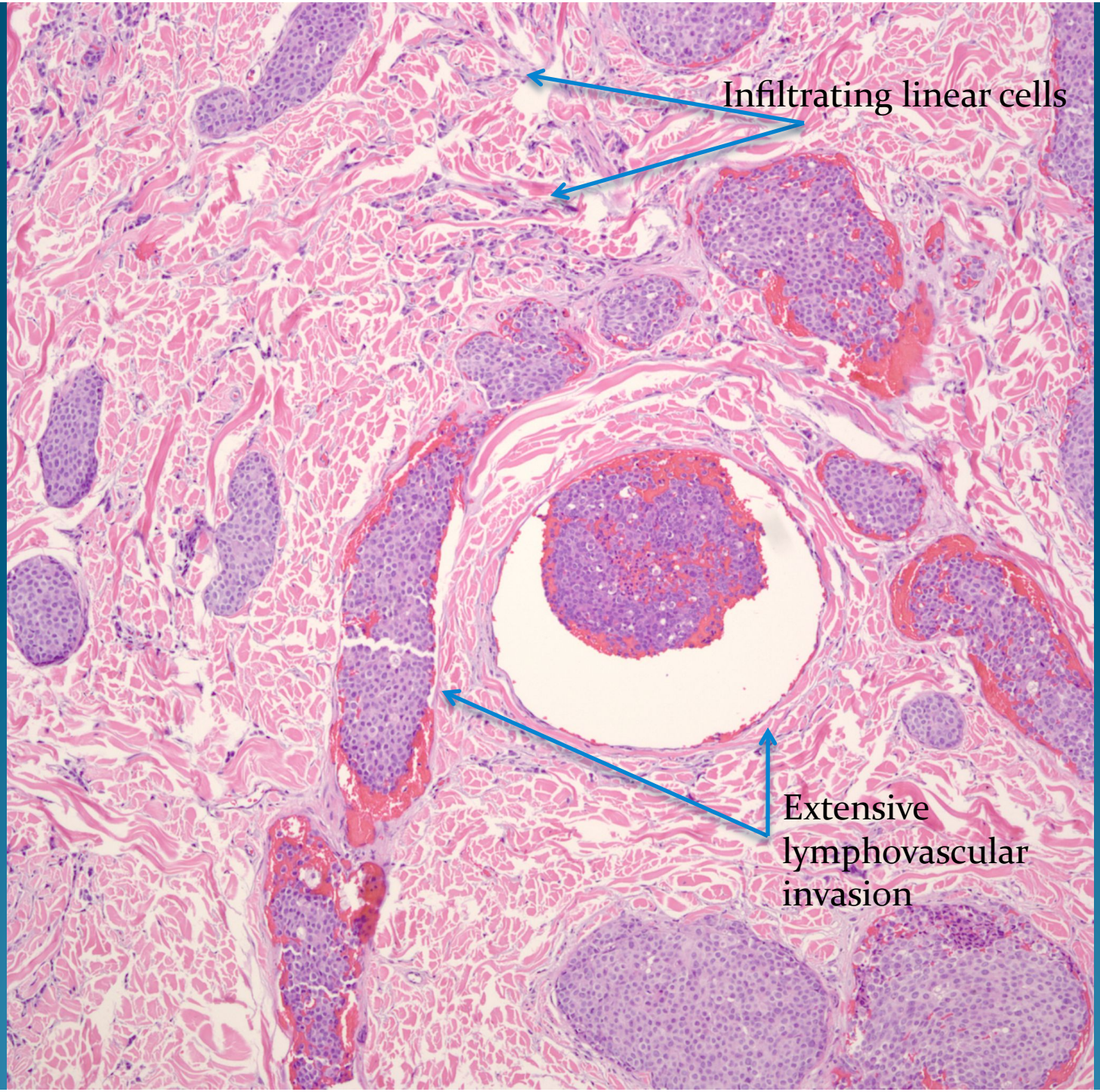
Infiltrating linear cells
Extensive lymphovascular invasion

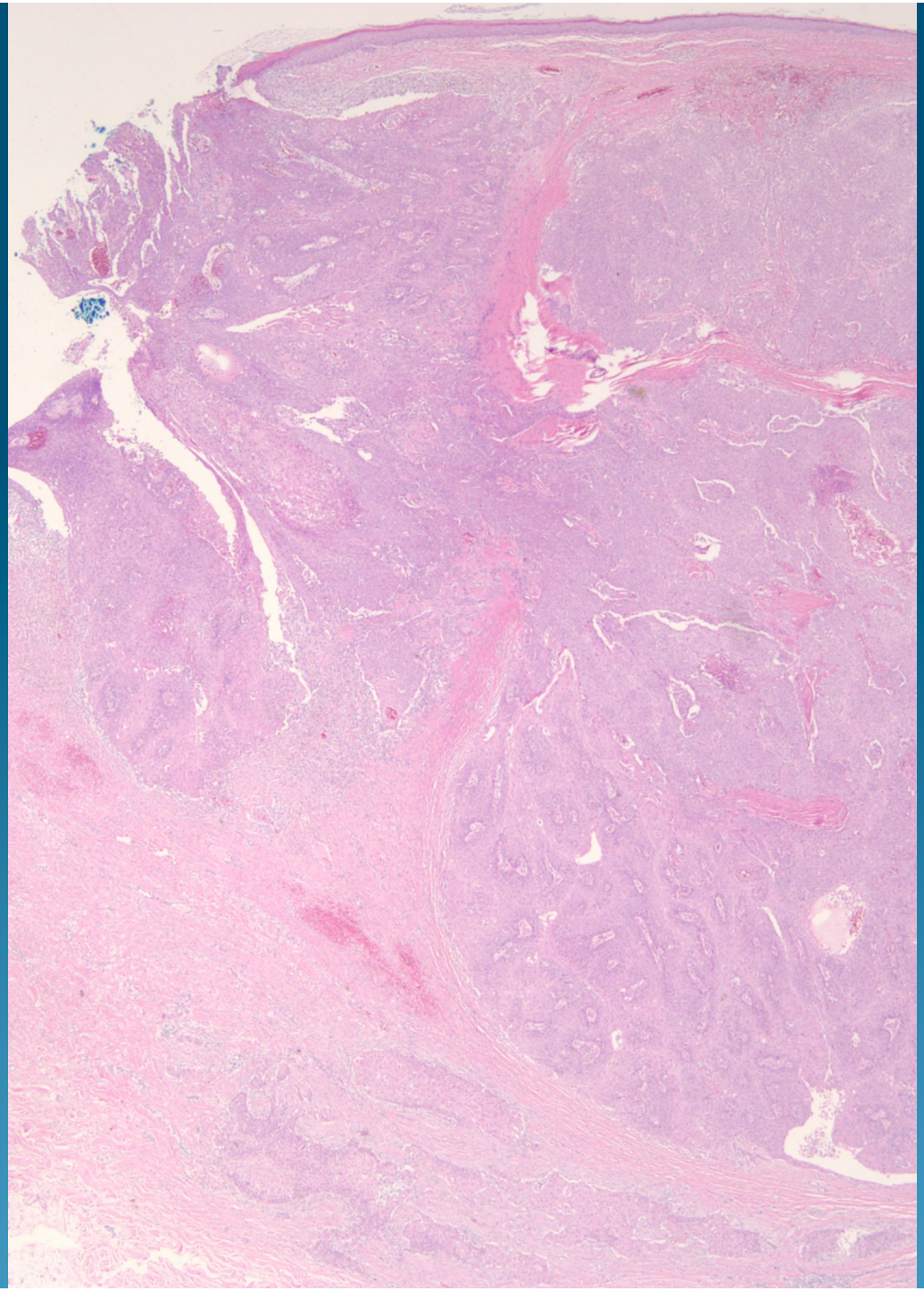

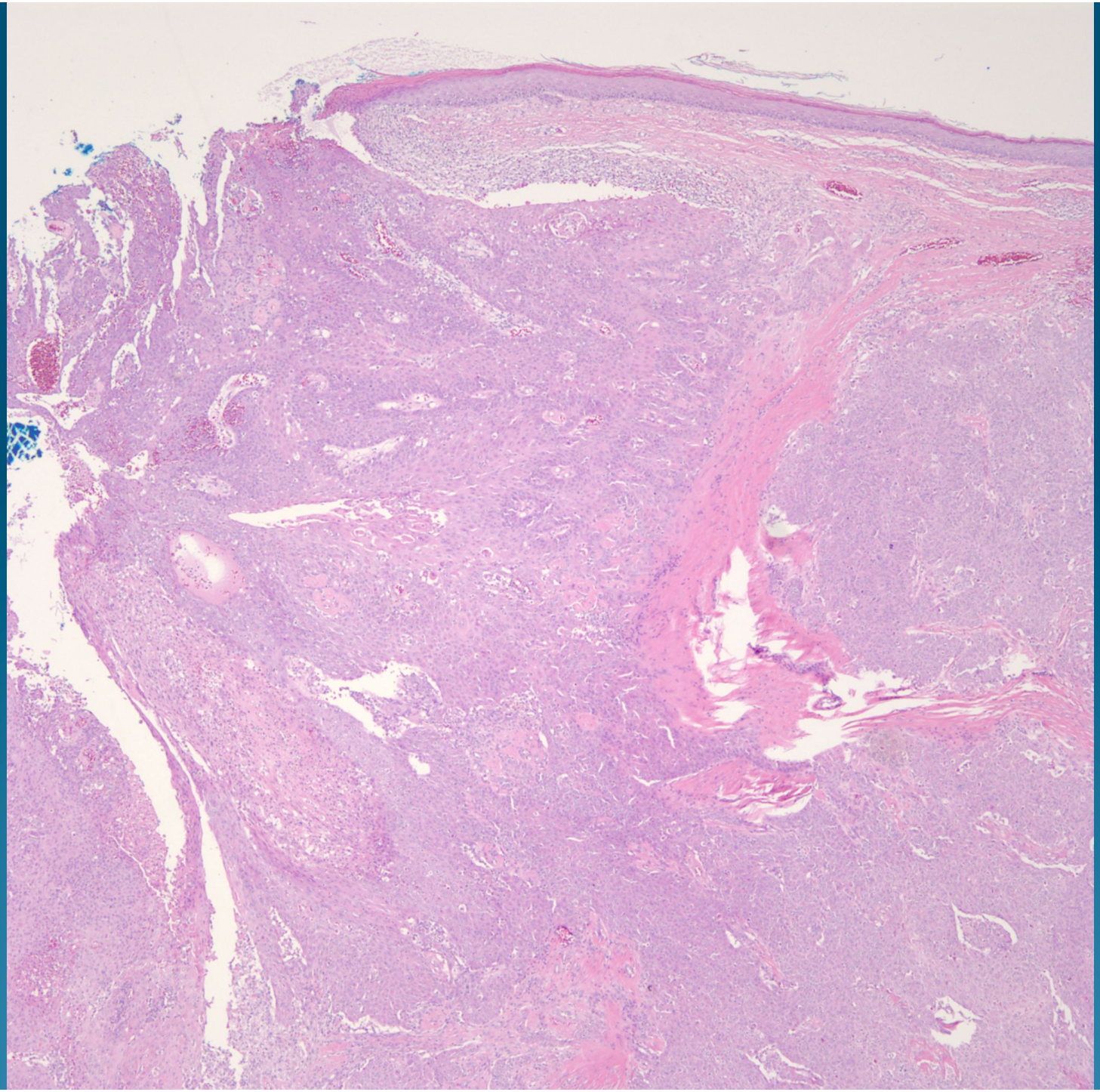

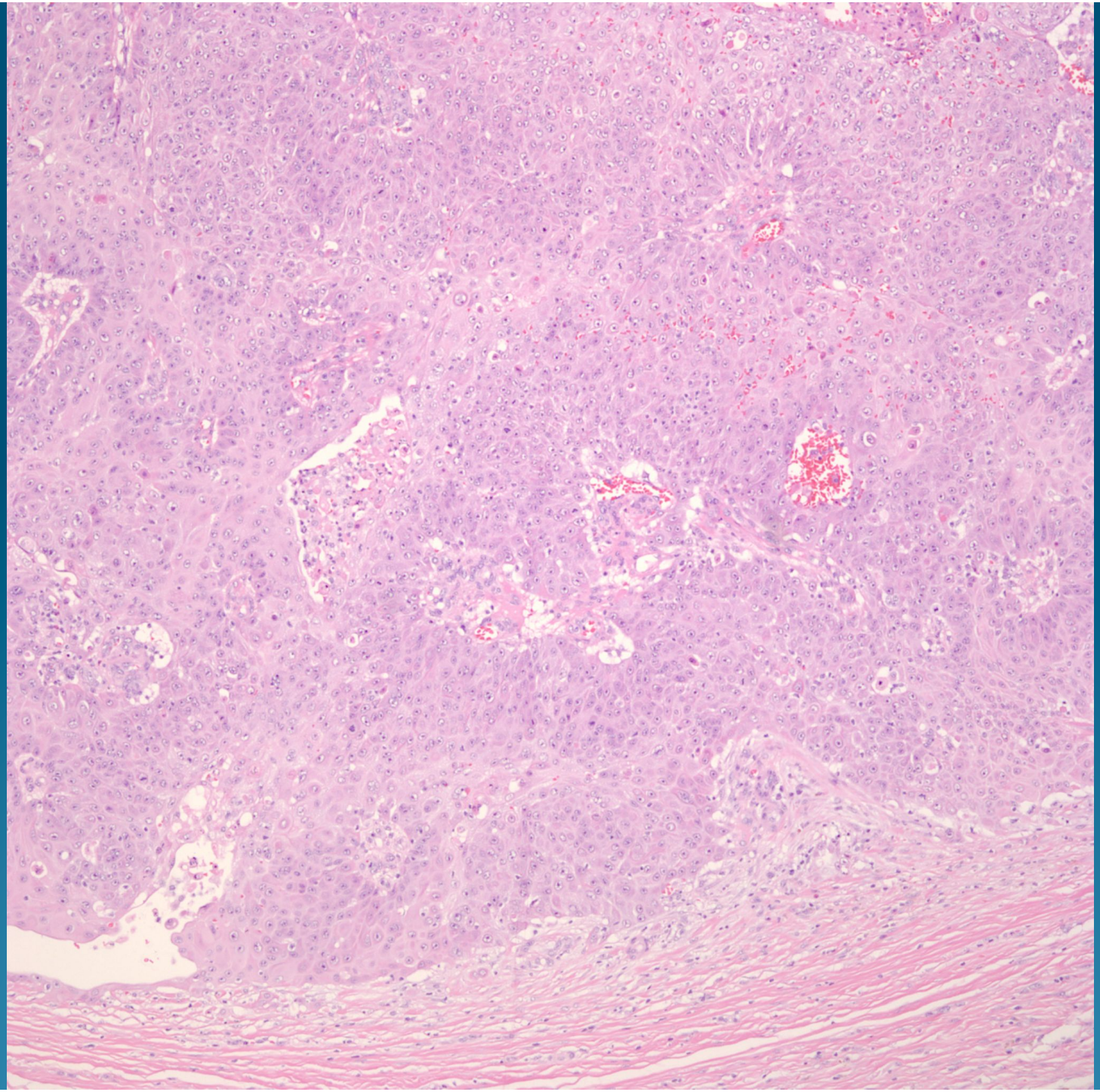

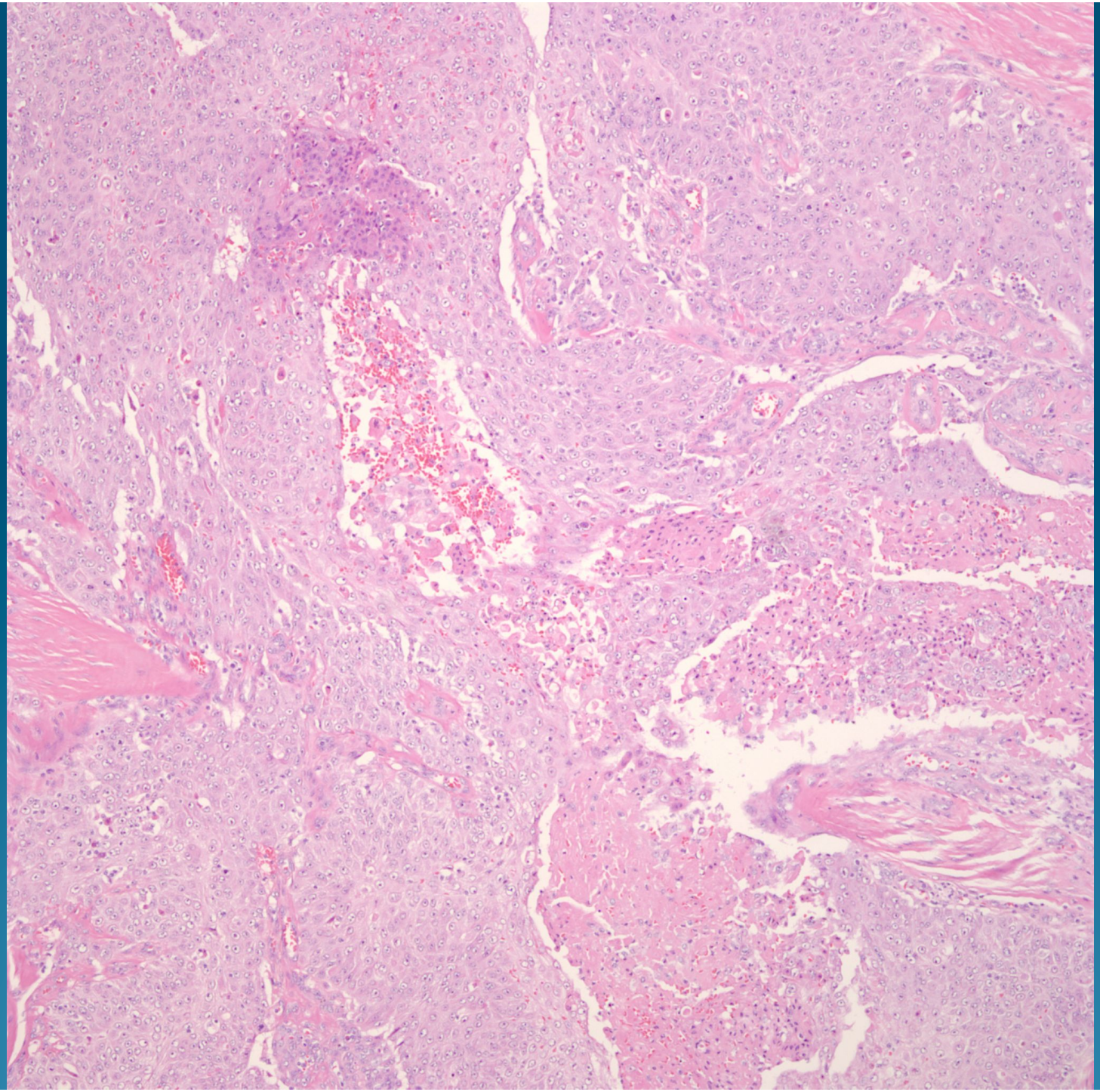

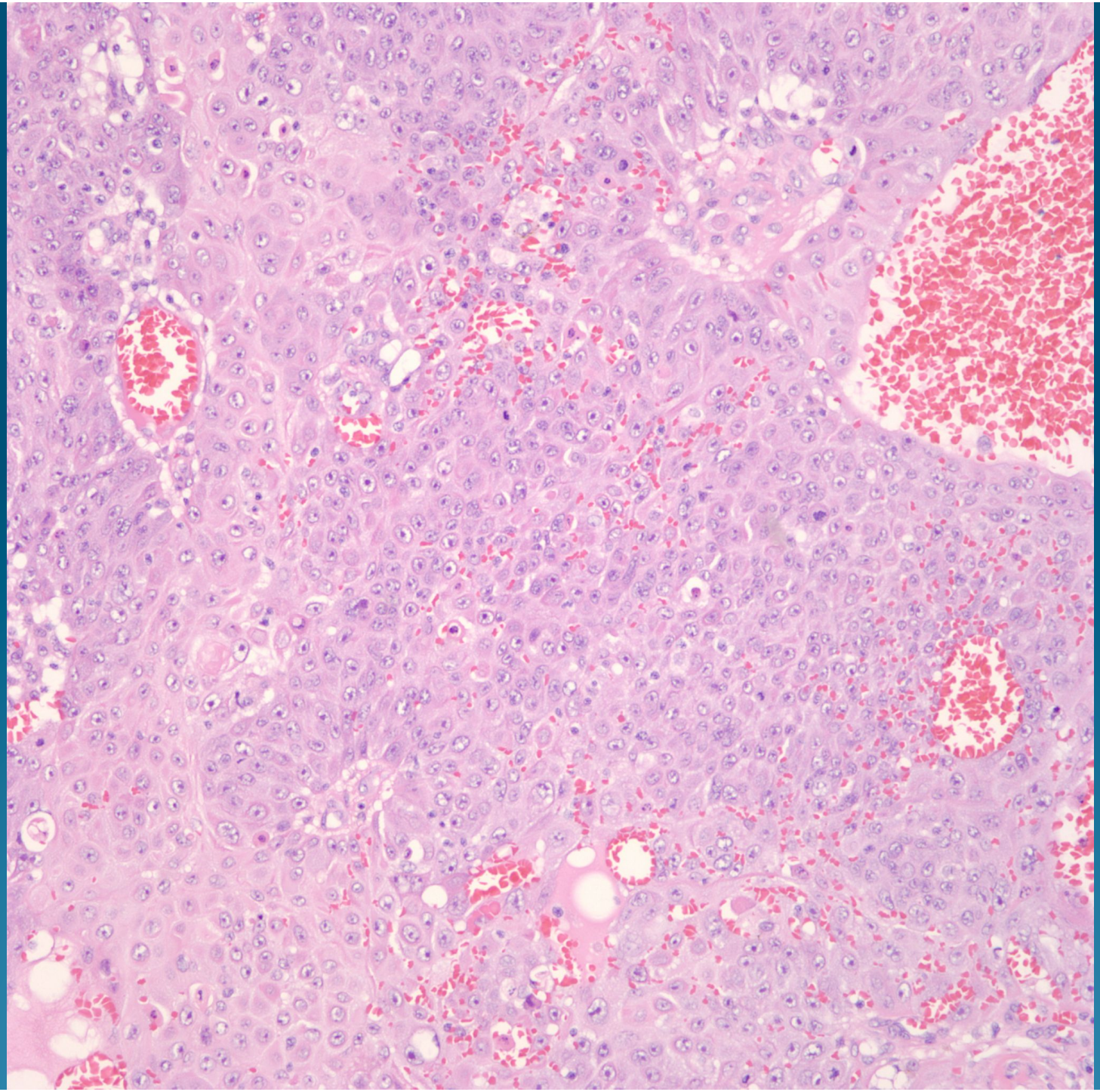

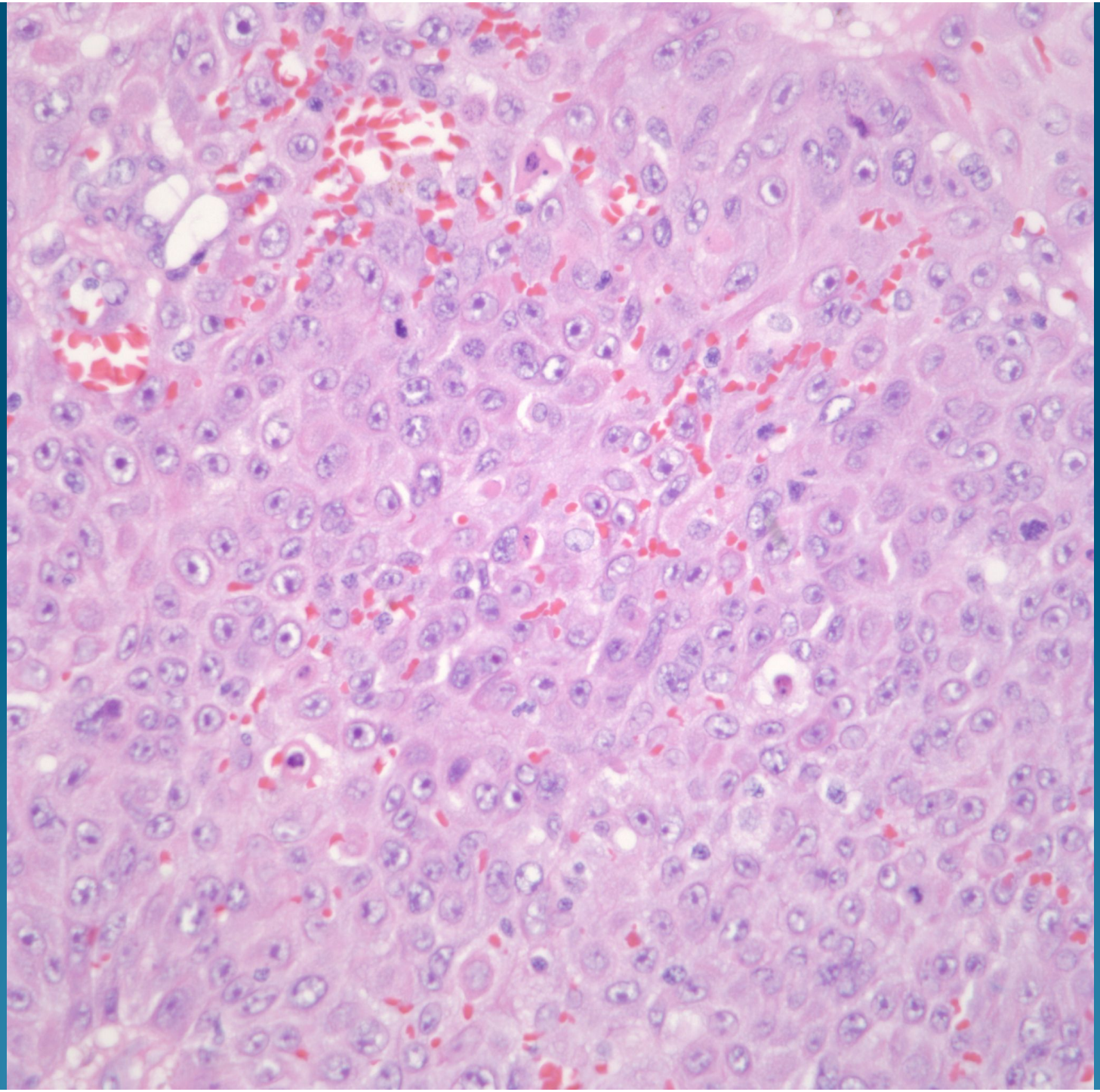

What is the best diagnosis?

A. Squamous cell carcinoma
B. Hidradenocarcinoma
C. Nodular basal cell carcinoma
D. Proliferating pilar tumor
E. Trichoblastoma

Hidradenocarcinoma, Low Grade

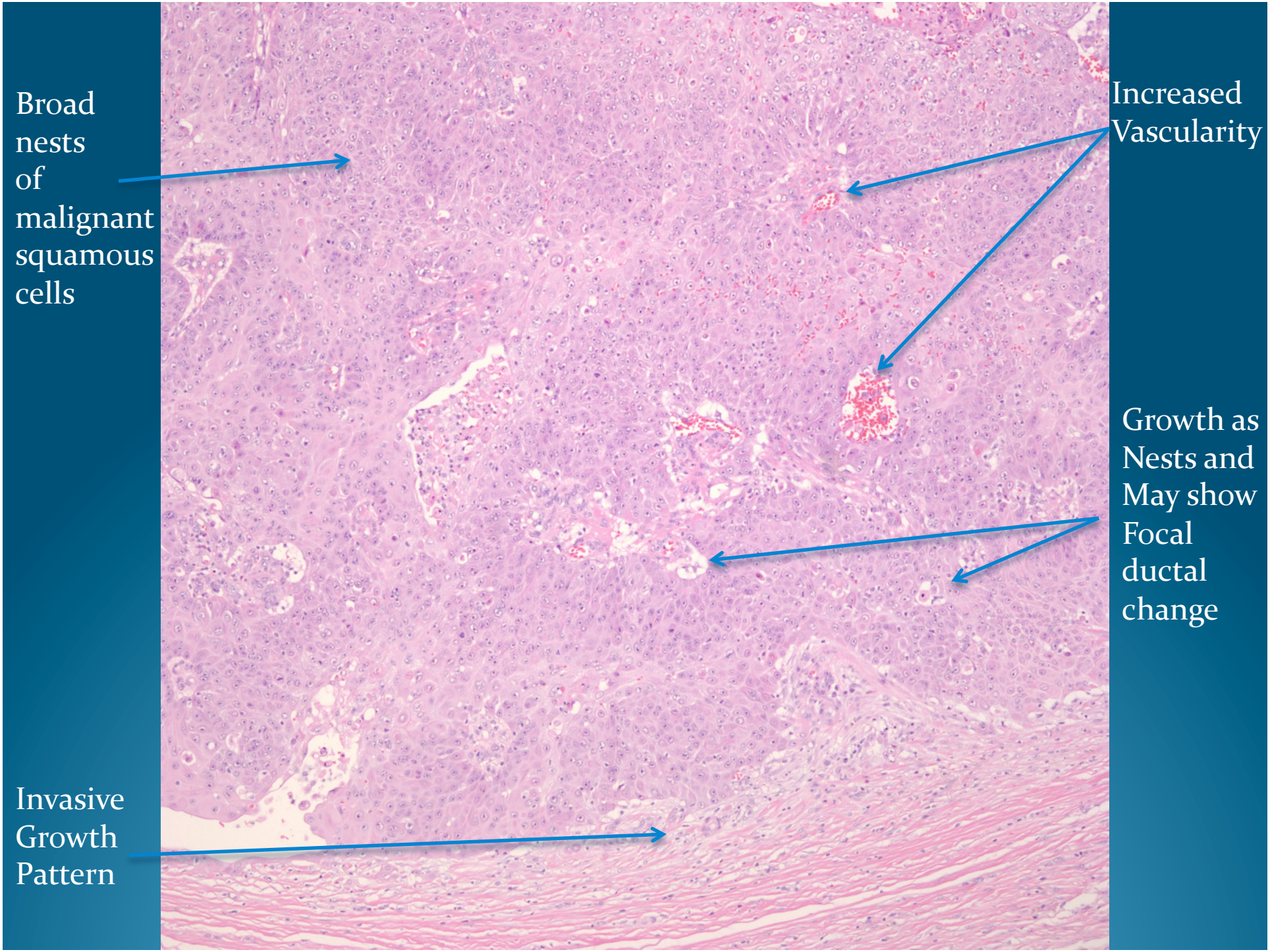
Broad nests of malignant squamous cells
Increased Vascularity
Growth as Nests and May show Focal ductal change
Invasive Growth Pattern

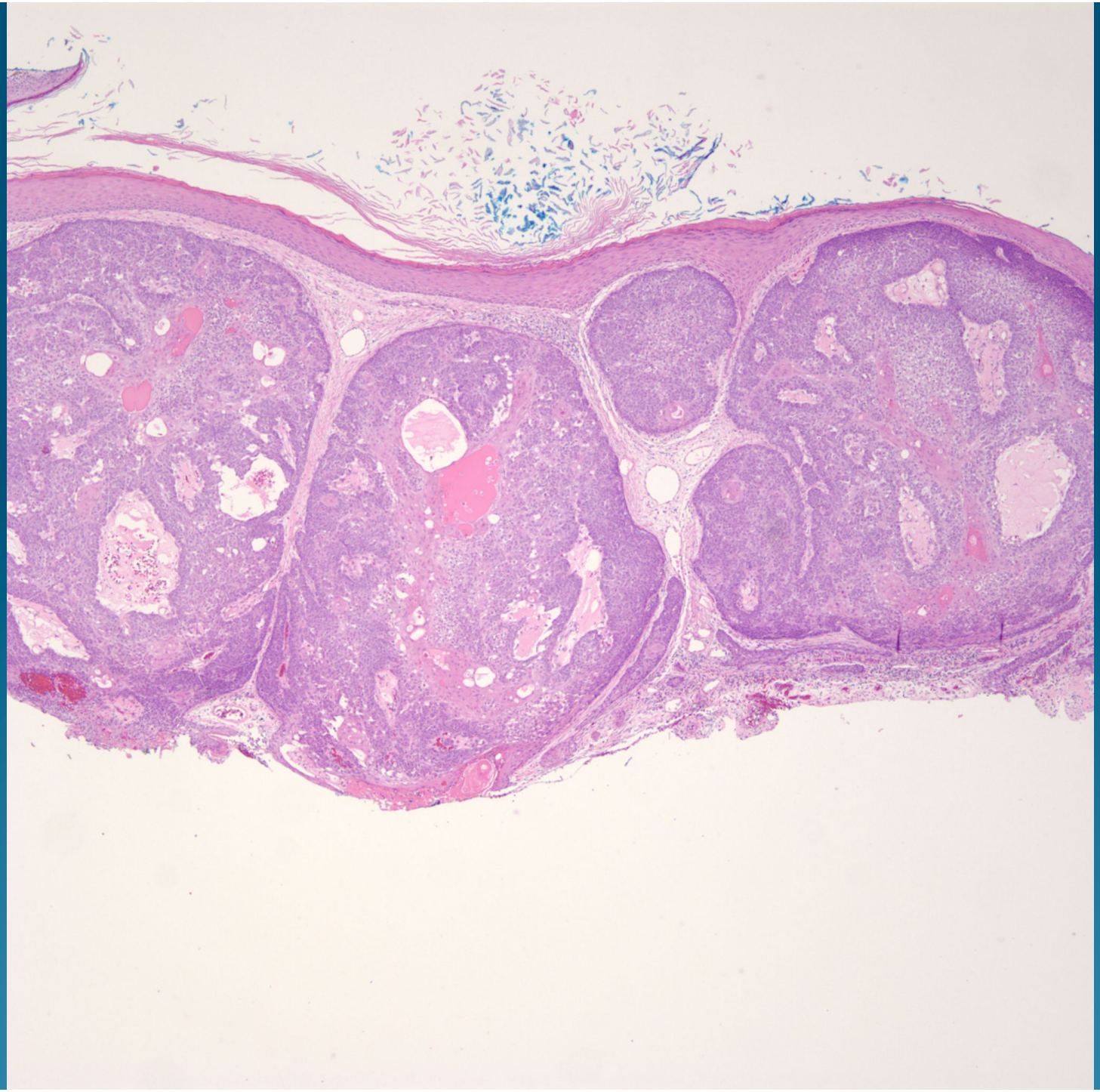

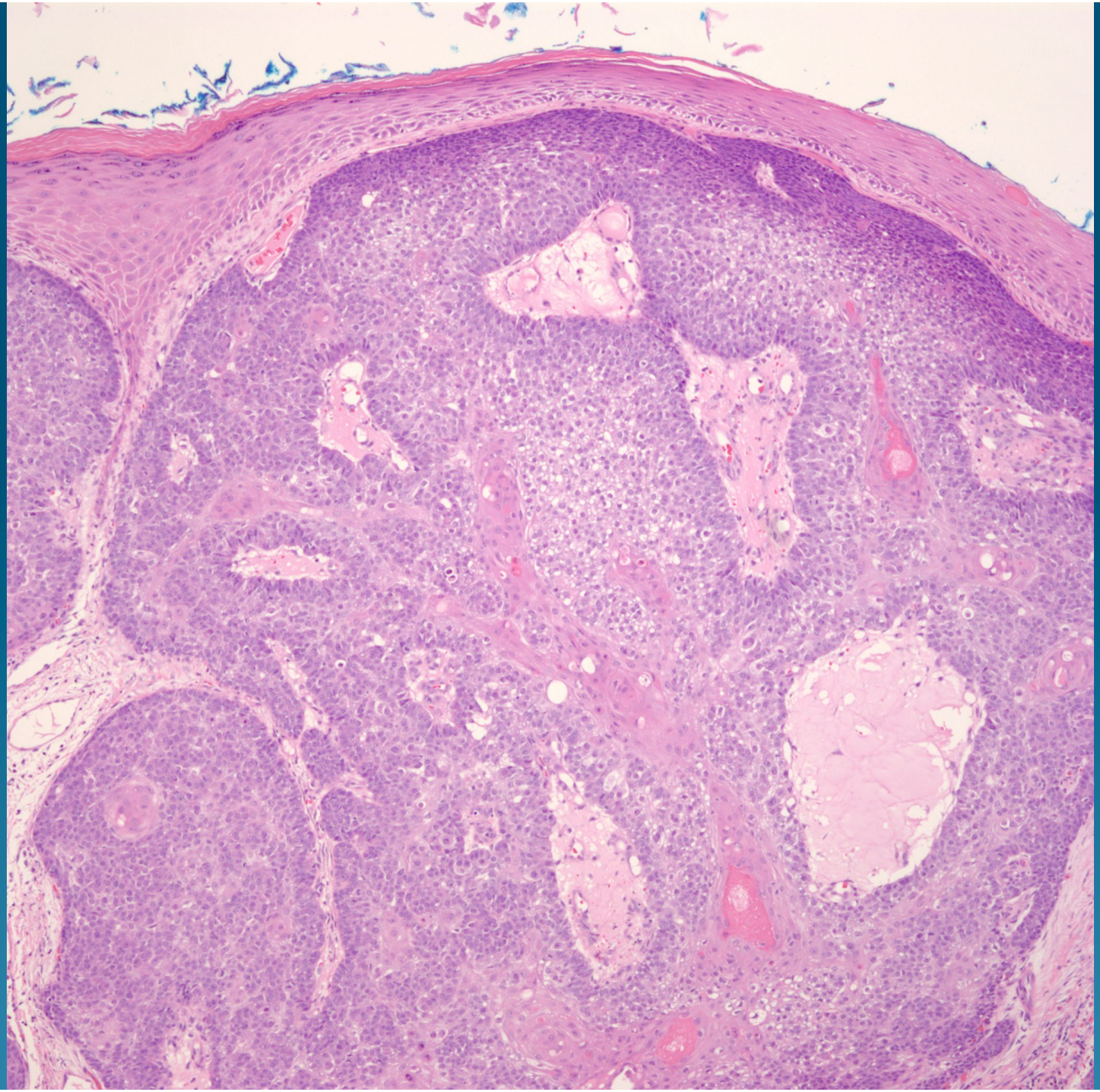

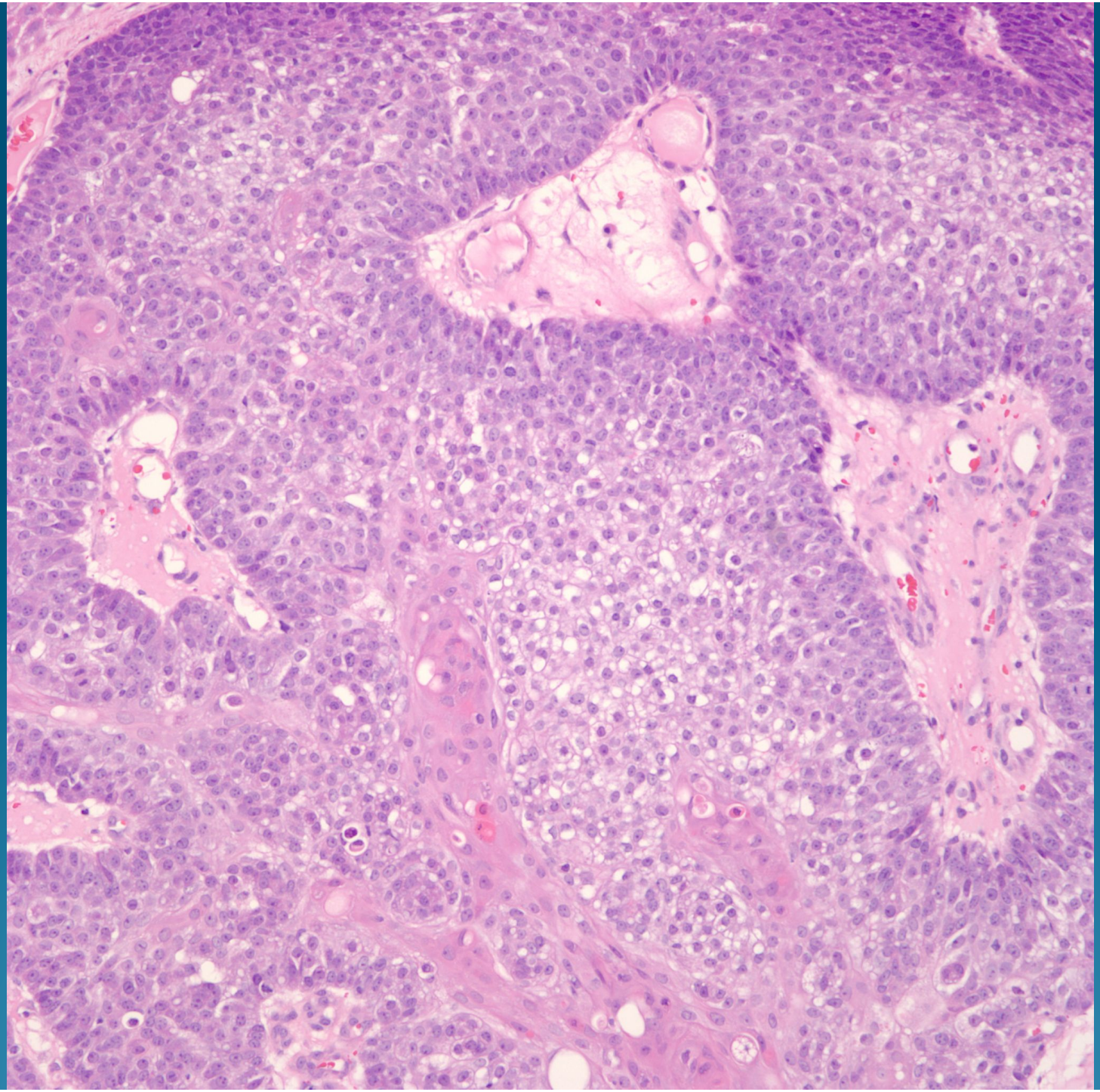

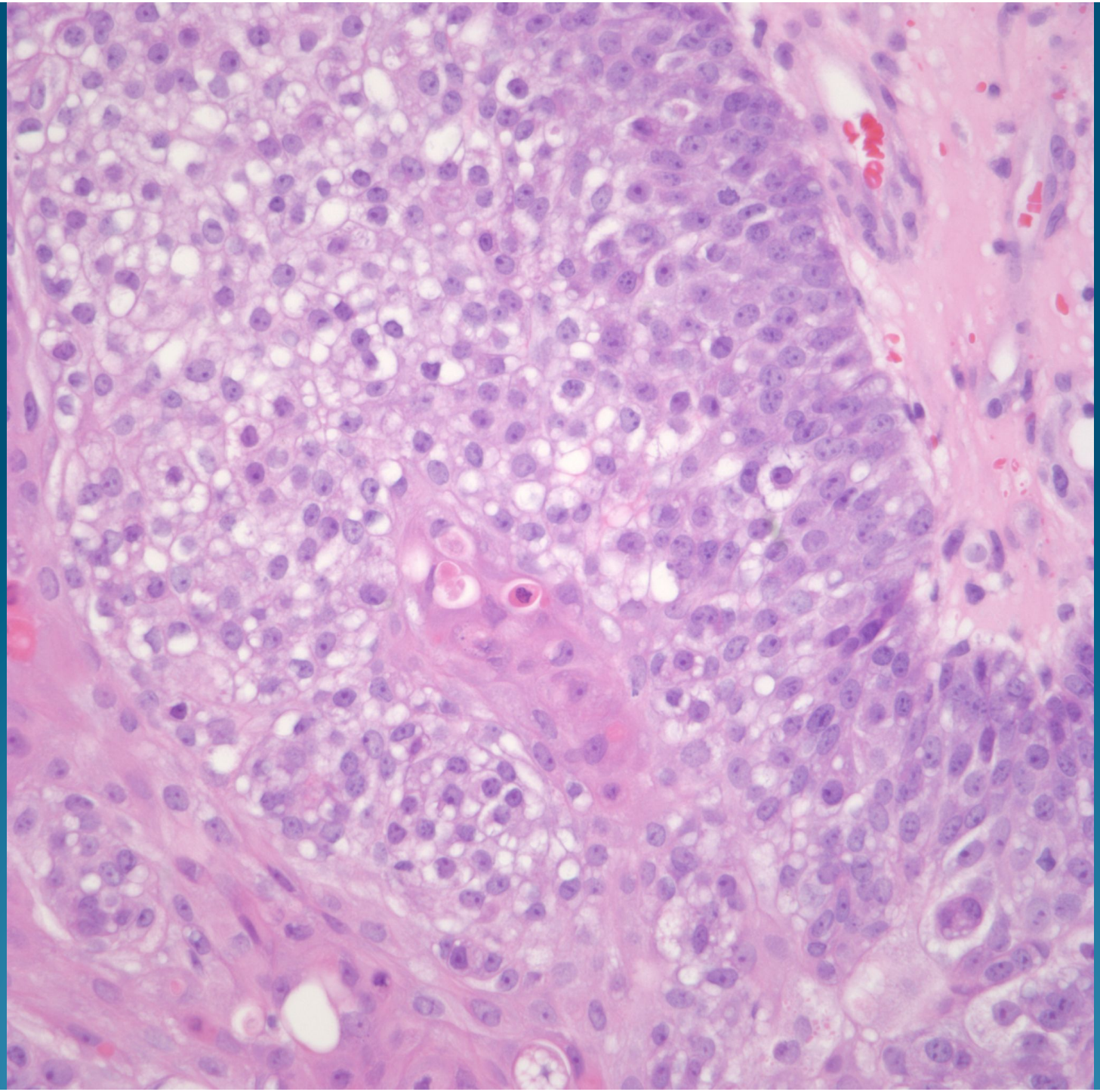

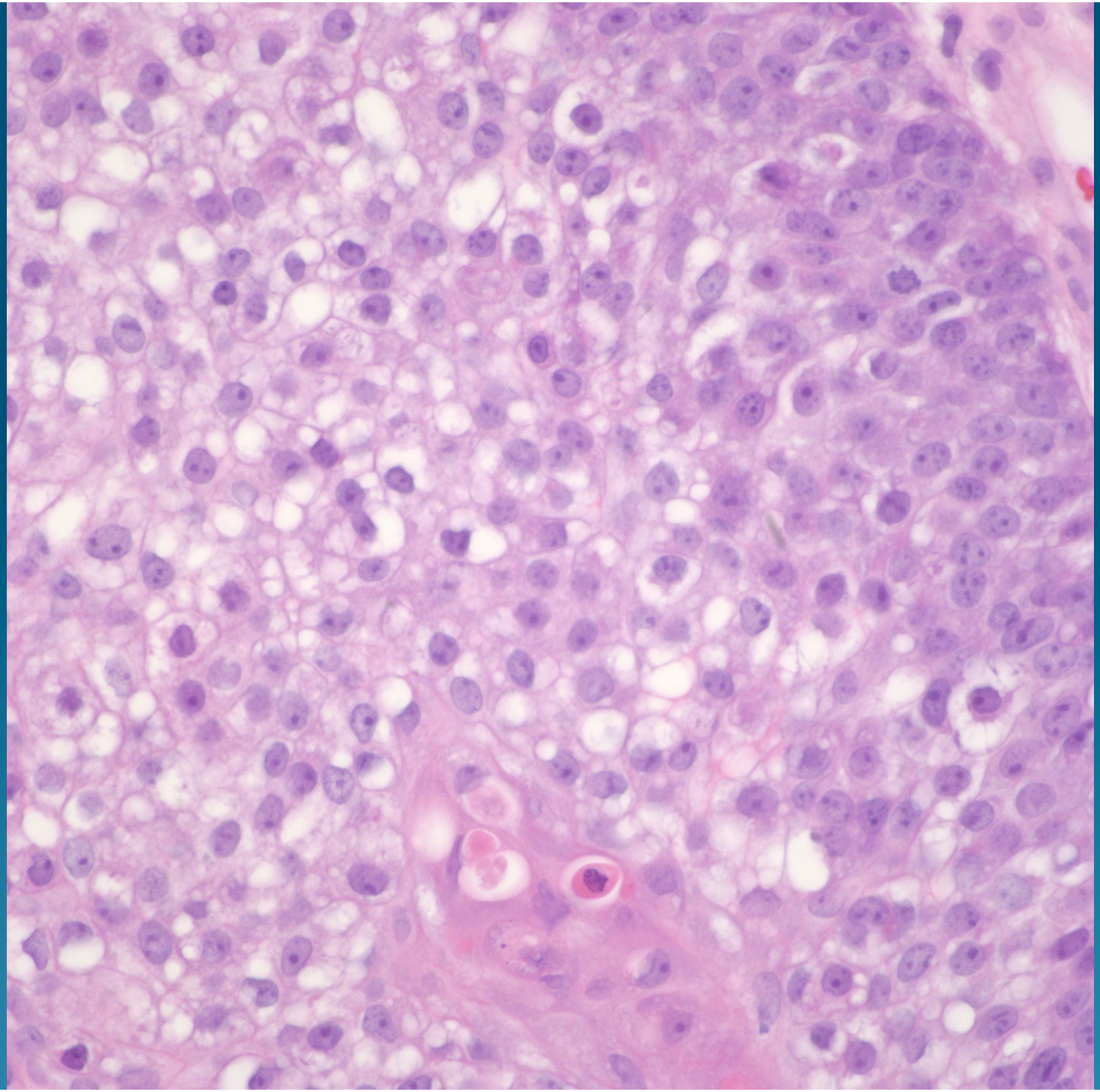

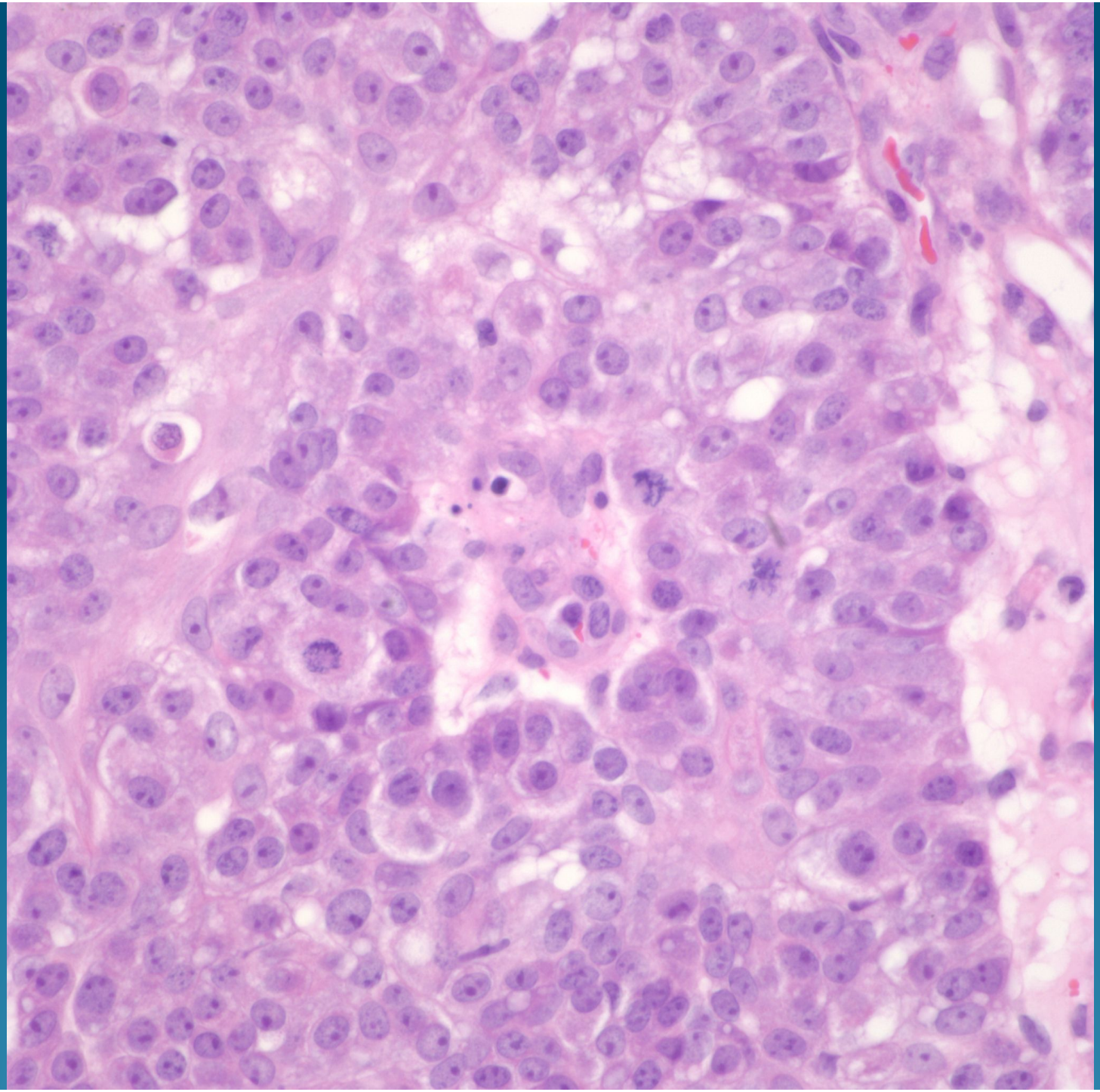

What is the best diagnosis?

A. Proliferating Pilar Tumor
B. Squamous Cell Carcinoma
C. Nodular Basal Cell Carcinoma
D. Hidradenocarcinoma
E. Sebaceous Carcinoma

Sebaceous Carcinoma

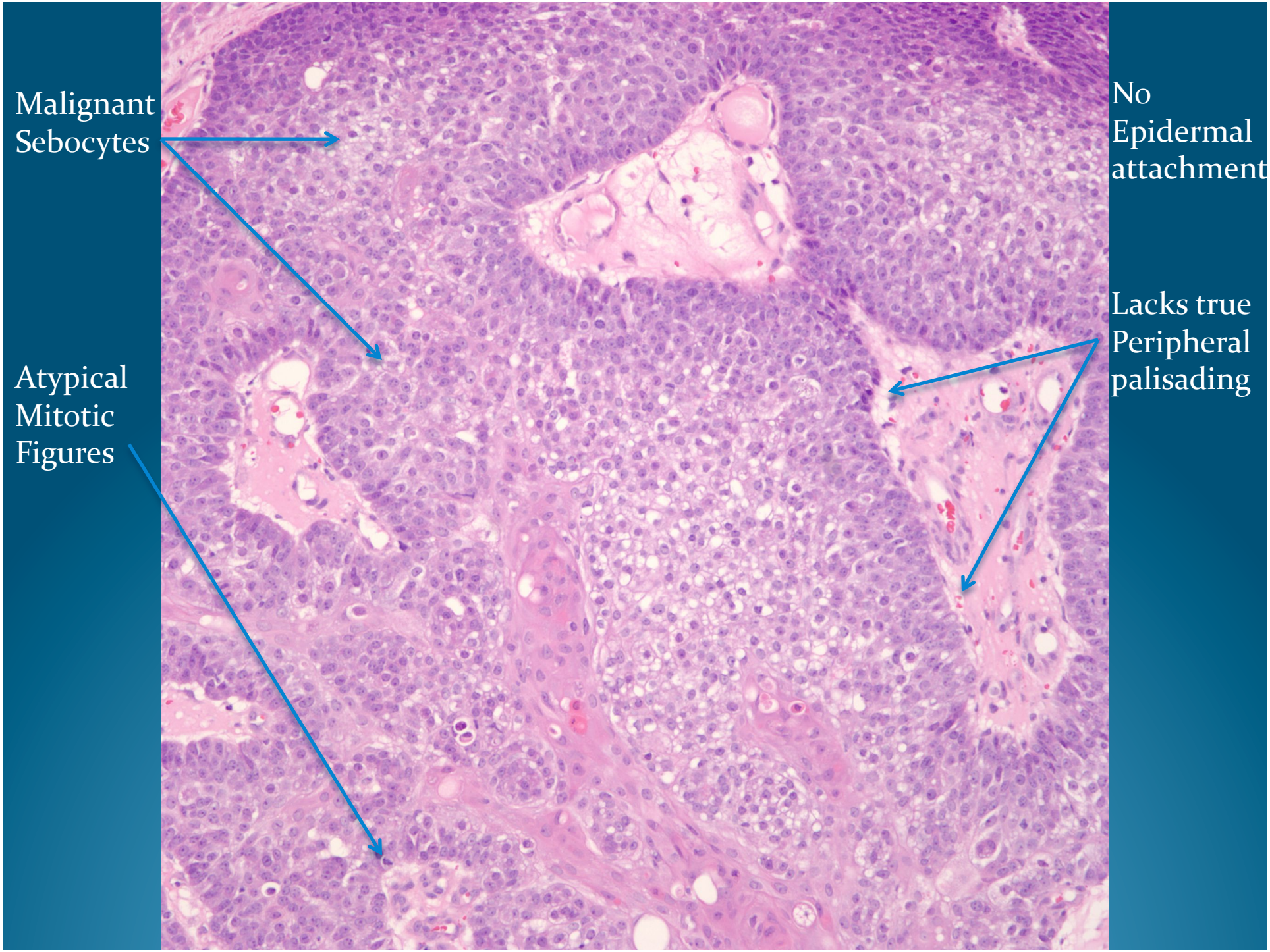
Malignant Sebocytes
Atypical Mitotic Figures
No Epidermal attachment
Lacks true Peripheral palisading